

DOI: 10.4274/jtad.galenos.2023.29491

J Turk Acad Dermatol 2023;17(1):31-34

Variable Clinical Features of Temporal Triangular Alopecia

© Güldehan Atış¹, © Gaye Güldiken², © Ayşenur Şam Sarı³

¹Istanbul Goztepe Prof. Dr. Suleyman Yalcin State Hospital, Clinic of Dermatology, Istanbul, Turkey

²Artvin Hopa State Hospital, Clinic of Dermatology, Artvin, Turkey

³Amasya University Sabuncuoglu Serefeddin Training and Research Hospital, Clinic of Dermatology, Amasya, Turkey

ABSTRACT

Temporal triangular alopecia (TTA), in other words congenital triangular alopecia, is an asymptomatic, non-cicatricial, permanent type of alopecia. Although it is often localized unilaterally in the frontotemporal region, it can occur bilaterally. Despite various associations with TTA have been reported, its association with sebaceous nevus has not been reported so far. In this article, we aim to report a possible association between TTA and sebaceous nevus and to report a pinkish background as a trichoscopic finding of TTA in addition to previously described trichoscopic findings.

Keywords: Nevus sebaceus, Temporal triangular alopecia, Trichoscopy

Introduction

Temporal triangular alopecia (TTA), in other words congenital triangular alopecia, is an asymptomatic, non-cicatricial, permanent type of alopecia. Although it is often localized unilaterally in the frontotemporal region, it can occur bilaterally [1]. Some associations have been reported as leukonychia, wooly hair, Down syndrome, sectorial hyperpigmentation of iris, epilepsy, mental retardation, phakomatosis pigmentovascularis, aplasia cutis congenita, congenital heart disease, bone and tooth abnormalities [1,2]. In this study, we aim to report a new possible association with TTA and nevus sebaceous and describe our cases with TTA clinically and trichoscopically.

Case 1

A 30-year-old man applied our clinic with hair loss. He had a 3x1.5 cm triangular alopecic patch (Figure 1a) and a verrucous plaque, on his temporal and parietal-occipital area, respectively. Both lesions were asymptomatic and present since birth. On the triangular alopecic area, pigmented vellus hairs in different thicknesses surrounded by

terminal hairs and white hairs were found trichoscopically (Figure 1b). The lesion was diagnosed with TTA. The trichoscopy of the yellow verrucous plaque (Figure 2a) revealed transparent yellowish fingerlike projections (Figure 2b). The skin punch biopsy of the verrucous plaque was histopathologically compatible with nevus sebaceous.

Case 2

A thirty-nine-year-old woman was admitted to our clinic with 3x2 cm-sized, triangular alopecic patches, extending to the anterior scalp line, on both temporal areas (Figure 3a,b), since infancy. Trichoscopically, on a pinkish background, empty follicles, yellow dots, white hairs, pigmented vellus hairs with length and diameter diversity, surrounded by terminal hairs were detected (Figure 3c,d).

Case 3

A fourteen-year-old male patient applied to our dermatology outpatient clinic with a lancet shaped, 4x1 cm-sized alopecic patch on the left frontotemporal region (Figure 4a), since infancy. On trichoscopic evaluation pigmented vellus hairs of different length and epidermal scale on a pinkish background were detected.



Address for Correspondence: Güldehan Atış MD, Istanbul Goztepe Prof. Dr. Suleyman Yalcin State Hospital, Clinic of Dermatology, Istanbul, Turkey

Phone: +90 532 792 70 93 **E-mail:** guldehan.atish@gmail.com **ORCID ID:** orcid.org/0000-0001-5069-044X

Received: 13.06.2022 **Accepted:** 15.02.2023

©Copyright 2023 by the Society of Academy of Cosmetology and Dermatology / Journal of the Turkish Academy of Dermatology published by Galenos Publishing House.

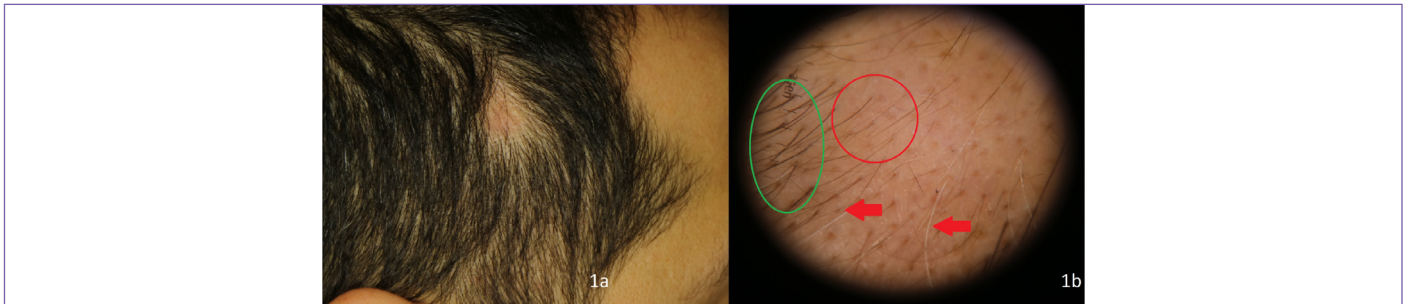


Figure 1. a. Triangular alopecic area, b. pigmented vellus hairs in different thickness (red circle) surrounded by terminal hairs (green circle) and white hairs (red arrows)

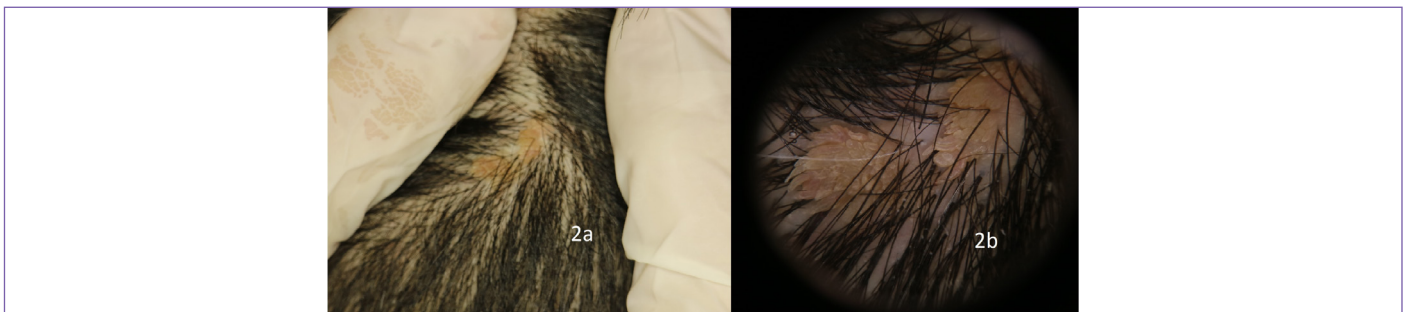


Figure 2. a. Yellow verrucous plaque, b. transparent yellowish fingerlike projections

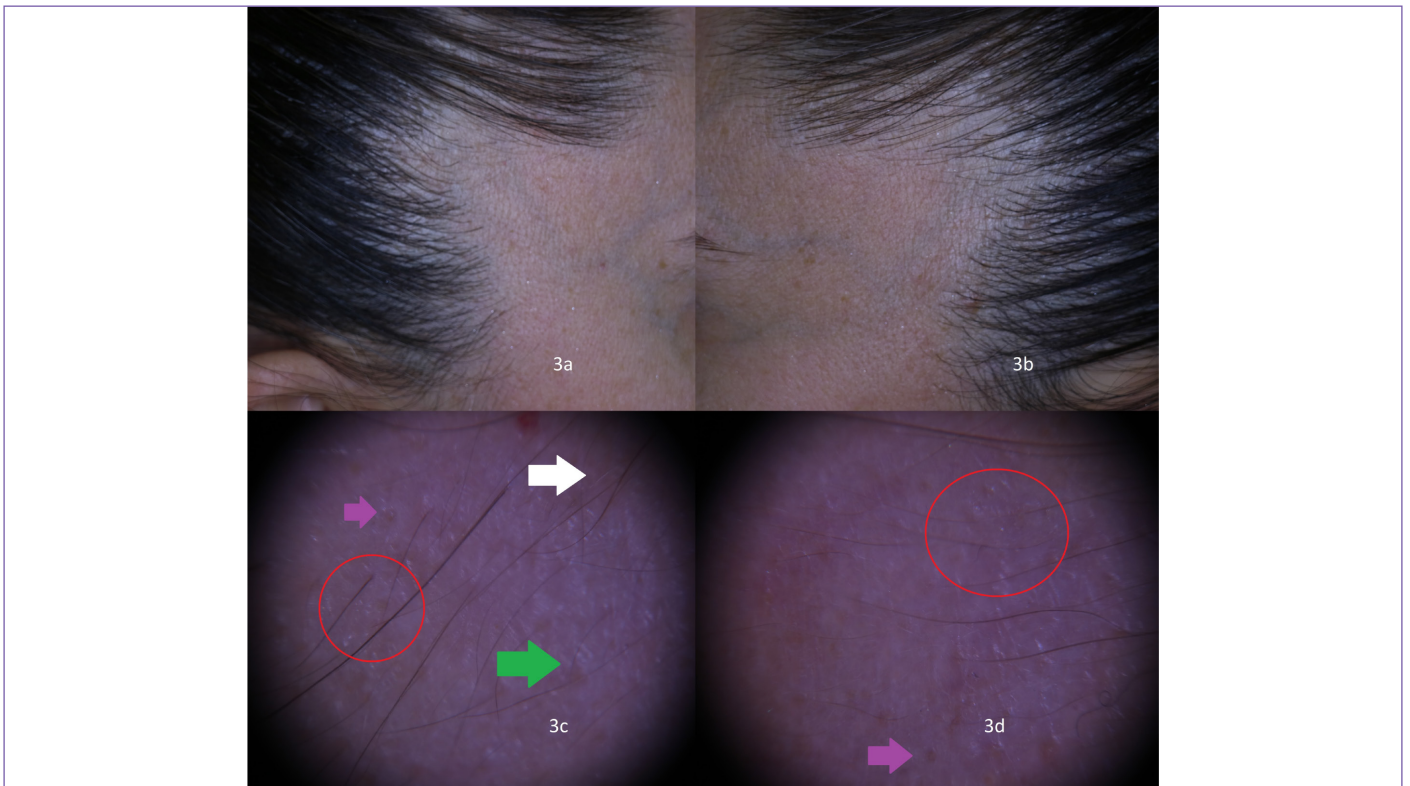


Figure 3. a,b. Alopecic areas were triangular shape 3x2 cm in size extending to the anterior scalp line, c,d. pigmented vellus hairs of different length and diversity, empty follicles, yellow dots, white hairs on pinkish background

Case 4

A twenty-year-old male patient presented with the complaint of an alopecic area since childhood. On dermatological examination, in the right frontotemporal region, a 3x1 cm lancet-shaped alopecic region was found (Figure 5).

Discussion

TTA is a kind of non-cicatricial alopecia that is often diagnosed in childhood and is usually observed in the frontotemporal region [3]. Although various associations have been reported in the literature, as far as we know, its association with nevus sebaceous has not been reported far.

Nevus sebaceous is a kind of hamartoma that is classically localized on the face or scalp [4]. Although it often occurs as an isolated lesion as in our TTA patient, especially extensive lesions can be accompanied by other system malformations such as brain, kidneys,

bones, and heart [4]. The occurrence of two rare entities in the same patient on the scalp may be coincidental. In the light of cases to be reported in the future, conditions that may accompany isolated lesions will be revealed.

In the literature, white hairs, white dots, vellus hairs surrounded by terminal hairs, empty follicles and diameter diversity are described as common trichoscopic features of TTA [1,5]. In addition to the features described, we observed a pinkish background in two of our cases (case 2,3). In the literature, an arboriform vascular pattern and arborizing red lines were reported [1,5]. In our opinion, the pinkish color can be associated with vascular structures that we could not observe because of their deeply localization or insufficient illumination.

TTA is usually diagnosed in early childhood, rarely it can be diagnosed in adulthood [6]. Other childhood non-cicatricial alopecias like alopecia areata, aplasia cutis congenita, tractional

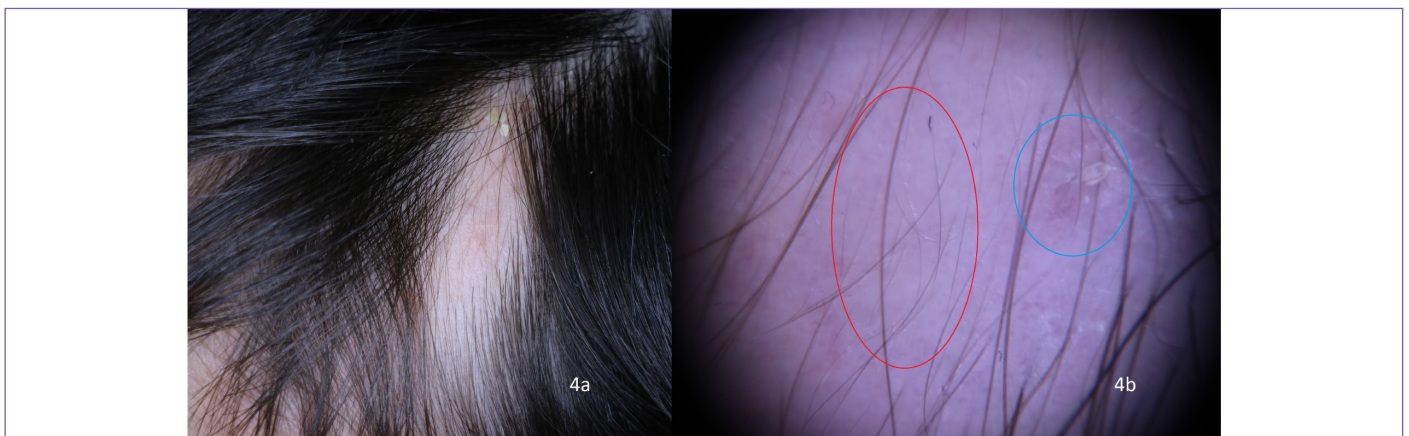


Figure 4. a. A lancet-shaped alopecic patch measuring 4x1 cm in size, b. Different lengths pigmented vellus hairs and epidermal scale on pinkish background

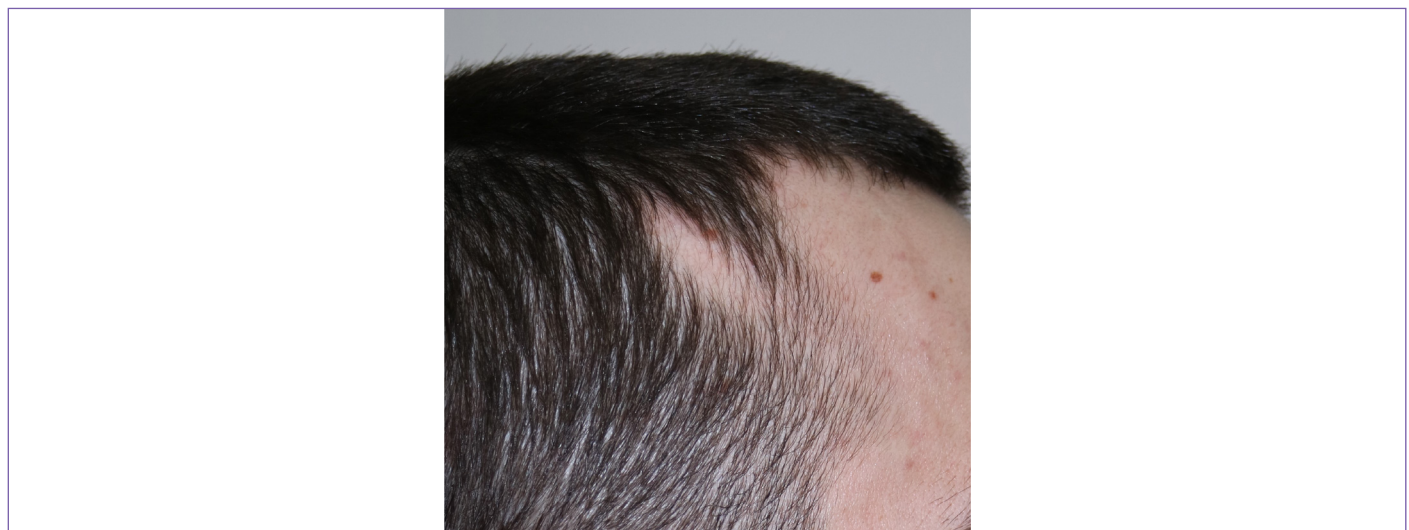

Figure 5. A lancet-shaped alopecic region, 3x1 cm in diameter, in the right frontotemporal region

alopecia, trichotillomania should be ruled out [1]. Absence of trichoscopic features of alopecia areata such as yellow dots, black dots, exclamation mark hairs, flame hairs, tapered hairs, pigtail hairs is distinctive [7]. Trichoscopy can also differentiate aplasia cutis congenita and TTA. Translucent appearance and absence of skin appendages are characteristic features of aplasia cutis congenita [5]. In contrast, eccrine pores are observed as white dots and numerous vellus hairs are seen in TTA [5].

In conclusion, trichoscopy is a non-invasive and useful method that can be used in the diagnosis of TTA and a pinkish background may take part as a trichoscopic feature. Evaluation of cases with TTA in terms of the presence of nevus sebaceous will be useful to find out the frequency of this association.

Ethics

Informed Consent: Patient consent has been obtained.

Peer-review: Externally and internally peer-reviewed.

Authorship Contributions

Surgical and Medical Practices: G.A., G.G., A.Ş.S., Concept: G.A., Design: G.A., A.Ş.S., Data Collection or Processing: G.A., G.G., Literature Search: G.G., A.Ş.S., Writing: G.A.

Conflict of Interest: No conflict of interest was declared by the authors.

Financial Disclosure: The authors declared that this study received no financial support.

References

1. Fernández-Crehuet P, Vaño-Galván S, Martorell-Calatayud A, Arias-Santiago S, Grimalt R, Camacho-Martínez FM. Clinical and trichoscopic characteristics of temporal triangular alopecia: A multicenter study. *J Am Acad Dermatol* 2016;75:634-637.
2. Campos JG, Oliveira CM, Romero SA, Klein AP, Akel PB, Pinto GM. Use of dermoscopy in the diagnosis of temporal triangular alopecia. *An Bras Dermatol* 2015;90:123-125.
3. Unger R, Alsufyani MA. Bilateral Temporal Triangular Alopecia Associated with Phakomatosis Pigmentovascularis Type IV Successfully Treated with Follicular Unit Transplantation. *Case Rep Dermatol Med* 2011;2011:129541.
4. El Ezzi O, de Buys Roessingh AS, Bigorre M, Captier G. Syndromic sebaceous nevus: current findings. *Int J Dermatol* 2018;57:599-604.
5. Karadağ Köse Ö, Güleç AT. Temporal triangular alopecia: significance of trichoscopy in differential diagnosis. *J Eur Acad Dermatol Venereol* 2015;29:1621-1625.
6. Yamazaki M, Irisawa R, Tsuboi R. Temporal triangular alopecia and a review of 52 past cases. *J Dermatol* 2010;37:360-362.
7. Atış G, Ferhatoglu ZA. Trichoscopic clues for the diagnosis of alopecia areata. *Turkderm Turkish Arch Dermatology Venereol* 2019;54:76-78.