

DOI: 10.4274/jtad.galenos.2023.21939

J Turk Acad Dermatol 2023;17(3):76-79

Can We Recognize Skin Adnexal Tumours? Retrospective Evaluation of Clinical and Histopathologic Data in a Tertiary Dermatology Clinic

© Muazzez Çiğdem Oba¹, © Meryem Yüvrük²

¹University of Health Sciences Turkey, Istanbul Sancaktepe Sehit Prof. Dr. Ilhan Varank Training and Research Hospital, Clinic of Dermatology and Venereology, Istanbul, Turkey

²University of Health Sciences Turkey, Istanbul Sancaktepe Sehit Prof. Dr. Ilhan Varank Training and Research Hospital, Clinic of Pathology, Istanbul, Turkey

ABSTRACT

Background: Clinical diagnosis of skin adnexal tumours (SATs) is challenging. In this study, we aimed to determine the compatibility rate of clinical pre-diagnoses and histopathological diagnoses in histopathologically confirmed cases of SATs examined by dermatologists.

Materials and Methods: Histopathologically confirmed cases of SATs in a single center dermatology clinic during May 2019- May 2023 were retrospectively retrieved. We recorded demographic characteristics, clinical characteristics (elementary lesion type, tumour localization, when available dermoscopic features) and clinical pre-diagnoses from patient medical records.

Results: A total of 39 SATs from 38 patients (18 female and 20 male) were included in the analysis. All 38 SATs (97.4%) were benign except one trichilemmal carcinoma. Lesions were most commonly located in head and neck region in 61.5% (n=24) of patients, presenting as nodules (n=21, 53.9%) and papule/plaques (n=18, 46.1%). Dermoscopic features included linear vessels, structureless white areas, structureless pink/purple areas and blue-gray dots. Clinical pre-diagnoses were discordant in 53.8% (n=21) of cases where SAT was not mentioned among one or more pre-diagnoses. Most common erroneous pre-diagnoses were epidermal cyst, nevi and non melanoma skin cancer.

Conclusion: With the exclusion of pilomatricoma, more than half of SATs are difficult to recognize in clinical and dermoscopic examination. Further studies with focus on clinical and dermoscopic differentiation of SATs from most common pitfall diagnoses are needed.

Keywords: Adnexal tumors, Clinicopathologic correlation, Hair follicle, Pilomatricoma, Sebaceous, Sweat gland

Introduction

Skin adnexal tumours (SATs) refer to heterogenous group of tumours arising from hair follicle, sebaceous and sweat glands [1]. From dermatologists' perspective, SATs are important for several main reasons. SATs mostly have a non-specific clinical appearance, presenting frequently as asymptomatic papules or nodules [2,3]. Some SATs may point to underlying genetic conditions [1]. Malignant SATs are rare, however they might have an aggressive course with local invasion and distant metastasis [2].

In this study, we aimed to determine the compatibility rate of clinical pre-diagnoses and histopathological diagnoses in histopathologically confirmed cases of SATs. Our secondary aim was to document clinical and dermoscopic data of SAT cases.

Materials and Method

Histopathologically confirmed cases of SATs, diagnosed in the Pathology Clinic of University of Health Sciences Turkey, Istanbul Sancaktepe Sehit Prof. Dr. Ilhan Varank Training and Research



Address for Correspondence: Muazzez Çiğdem Oba MD, University of Health Sciences Turkey, Istanbul Sancaktepe Sehit Prof. Dr. Ilhan Varank Training and Research Hospital, Clinic of Dermatology and Venereology, Istanbul, Turkey

Phone: +90 530 142 65 41 **E-mail:** muazzez.oba@istanbul.edu.tr **ORCID ID:** orcid.org/0000-0002-9207-0748

Received: 24.08.2023 **Accepted:** 29.08.2023



Licensed under a Creative Commons Attribution-NonCommercial-NoDerivatives 4.0 (CC BY-NC-ND) International License.

Hospital, during May 2019- May 2023 were retrospectively retrieved. Hematoxylin and Eosin stained slides and immunohistochemical stains were used to establish diagnosis. Non-syndromic SAT cases who were examined by at least one dermatologist (with/without plastic surgeons, pediatric surgeons, general surgeons) were included in the study. We retrospectively noted demographic characteristics, clinical characteristics including elementary lesion type, tumour localization and when available dermoscopic features. Clinical pre-diagnoses and biopsy technique (punch/excision) were also recorded.

Before starting the study, approval was obtained from the Institutional Review Board of University of Health Sciences Turkey, Istanbul Sancaktepe Sehit Prof. Dr. Ilhan Varank Training and Research Hospital (decision no: 113, date: 21.06.2023).

Statistical Analysis

Descriptive statistics were presented with mean and standard deviation values. Categorical variables such as gender, tumour diagnosis, location were expressed in percentages.

Results

A total of 39 SATs from 38 patients (18 female and 20 male) were included in the analysis. Age range was from 7 to 82 years (41±21.5 years), most patients being in their fifth decade. Demographics of the patients can be seen in Table 1.

All 38 SATs (97.4%) were benign except one trichilemmal carcinoma. Histopathological diagnoses of the SATs and their origin are given in Table 2. Lesion origin was hair follicle in 59% (n=23) and sweat gland in 41% (n=16) of cases. None of the tumours were of sebaceous origin. Histopathologic confirmation was performed with total excision in 84.6% (n=33) and with punch biopsy in 15.4% (n=6) of cases.

Table 1. Characteristics of the patients (total=38)

Characteristics	n (%)
Gender	
Female	18
Male	20
Age range	
0-10	3 (7.9%)
11-20	5 (13.1%)
21-30	5 (13.1%)
31-40	5 (13.1%)
41-50	7 (18.4%)
51-60	5 (13.1%)
61-70	5 (13.1%)
71-80	1 (2.6%)
>80	2 (5.3%)

Lesions were most commonly located in head and neck region in 61.5% (n=24) of patients, followed by extremities (n=11, 28.2%) and trunk (n=4, 10.3%). In clinical examination, lesions were described as nodular (n=21, 53.9%) and papule/plaques (n=18, 46.1%). Dermoscopic features were available in medical records of 20 patients. Linear vessels (n=15), structureless white areas (n=10), structureless pink/purple areas and blue-gray dots (n=3) were noted. In 46.2% (n=18) of cases, SAT was suspected by examining dermatologist. Among 12 pilomatricoma cases, 58.3% (n=7) were correctly identified. Clinical pre-diagnoses were discordant in 53.8% (n=21) of cases where SAT was not mentioned among one or more pre-diagnoses. Erroneous pre-diagnoses were epidermal cyst (n=16), nevus (dermal/Spitz) (n=7), non-melanoma skin cancer (basal cell carcinoma, squamous cell carcinoma, Kaposi’s sarcoma, n=5) and verruca vulgaris (n=1). A demonstrative case can be seen in Figure 1.

Discussion

Thirty-nine histopathologically confirmed SAT cases were evaluated in dermatology our department during a four year period. This data points to a rare diagnosis, thus SATs are difficult to recognize for both dermatologists and pathologists [2,3]. Vast majority of SATs are benign tumours, with a proportion ranging from 69.41% to nearly 100% in different studies, as observed in our study [2,3,4,5]. Consistent with existing literature, in our cohort SATs were observed in a wide age range [1,2,3,4,6] with nearly 20% of patients being in their 5th decade [3]. Although some data report female preponderance in SAT cases [2,3] which may be attributed to cosmetically unacceptable

Table 2. Histopathological diagnoses according to tumour origin

Histopathologic diagnosis	Origin	n (%)
Pilomatricoma	Hair follicle	12 (30.8)
Syringoma	Sweat gland	4 (10.2)
Proliferated trichilemmal tumour	Hair follicle	4 (10.2)
Trichofolliculoma	Hair follicle	3 (7.7)
Syringocystadenoma papilliferum	Sweat gland	3 (7.7)
Chondroid syringoma	Sweat gland	2 (5.1)
Trichoblastoma	Hair follicle	2 (5.1)
Hidrocystoma	Sweat gland	2 (5.1)
Hidroadenoma	Sweat gland	2 (5.1)
Eccrine poroma	Sweat gland	1 (2.6)
Eccrine spiradenoma	Sweat gland	1 (2.6)
Hidroadenoma papilliferum	Sweat gland	1 (2.6)
Desmoplastic trichoepitelioma	Hair follicle	1 (2.6)
Trichilemmal carcinoma	Hair follicle	1 (2.6)

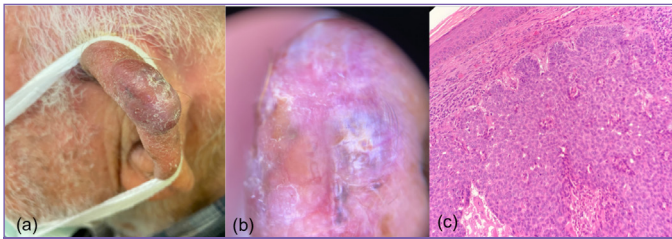


Figure 1. Clinical, dermatoscopic and histopathologic photographs of adnexal tumour (trichoblastoma) with clinical pre-diagnoses of basal cell carcinoma and Kaposi's sarcoma. (a): Clinically a solitary nodular lesion on the helix of a 81 year old man was observed. (b): Dermoscopy reveals purple structureless areas, shiny white lines, blue-gray ovoid nests. (c): Histopathologically a palisading uniform cellular proliferation with basaloid morphology as a dermal tumour nodule without epidermal connection was diagnosed as trichoblastoma (Hematoxylin and Eosin x200)

nature of the lesions [2], we did not observe a gender predilection in our series as Pujani et al. [5] and Bartoš [6], while other authors have reported a male preponderance [4]. Majority of the lesions are typically located in head and neck region, as this is an area rich in skin appendages [1,2,3,4,5,6,7].

In most studies, SATs arising from sweat glands outnumbered tumours with follicular or sebaceous differentiation [1,4,5,7]. However, similar to data from a Slovakian center, in our series follicular tumours were more common [6]. In the present study, the most common type of SAT was pilomatricoma as in many studies [4,8], followed by proliferating trichilemmal tumour (PTT). PTT was also reported to be frequent among SATs with hair follicle differentiation in another study [2]. Syringomas of our series was in equal number with PTTs. Of note, three out of four syringomas were located on trunk and extremities, where diagnostic difficulties are even increased. On the other hand, sebaceous SATs were not biopsied or excised in our series. SATs with sebaceous differentiation presented only 5% of a total of 1615 SATs biopsied or excised in the extensive study by Cook et al. [1] where sebaceous nevus was excluded from analysis. Similar to our results, very few cases of sebaceous SATs were reported in some series [2,6,7].

Clinically SATs present as non-specific asymptomatic papulonodules [2,3]. In addition, reported dermatoscopic features of SATs were also mostly non-specific, mimicking melanocytic lesions, non-melanoma skin cancer and other benign cutaneous disorders [9,10]. Consistent with literature, dermatoscopic features noted in our cohort were non-specific and even misleading. A very recent multi-center study by Longo et al. [11] better characterized dermatoscopic features of trichoepitheliomas. Ivory white background color, small, unfocused vessels and grey-purple structureless areas were most common dermatoscopic features of trichoepithelioma and trichoblastomas, while ulceration and erosion favored diagnosis of basal cell carcinoma [11].

In studies from various institutions from different countries, correctness rates of pre-biopsy diagnoses in SATs ranged from 6.4% to 48% [1,2,3,5,12]. The study by Aslan Kayiran et al. [3] conducted in an experienced tertiary dermatology clinic in Turkey has reported a clinicopathologic compatibility rate of 45%, similar to our cohort. This relatively high concordance rate in our study and in the latter study might be attributed to study design, as these were studies conducted by dermatologists. Studies involving SATs pre-diagnosed by all clinicians report lower rates of concordance [1,2,5,12]. Aslan Kayiran et al. [3] have noted higher concordance rate for the two most common subtypes of SAT in their series, which were sebaceous hyperplasia and pilomatricoma (65.2% and 50% respectively). Diagnostic accuracy of pilomatricoma was also higher (58.3%) in our series. Similar to our series, epidermal cysts, melanocytic and nonmelanocytic tumors were among most common erroneous clinical prediagnoses [2,3].

Definitive diagnosis of SATs relies on histopathologic examination [3]. As local surgical excision is curative in most cases [2], total excision is preferred over punch biopsies in diagnostic management of SATs. In our series, majority of cases were simultaneously diagnosed and treated with total excision.

Study Limitation

Limitations of the present study include its retrospective nature, which restricts available clinical data to medical records written by one examining dermatologist.

Conclusion

With the exclusion of pilomatricoma, more than half of SATs are difficult to recognize in clinical and dermatoscopic examination. Atypical localizations of commonly observed SATs also constitute a diagnostic concern. In our study, most common erroneous clinical pre-diagnoses were epidermoid cysts, nevi and non-melanoma skin cancers. Further studies with focus on clinical and dermatoscopic differentiation of SATs from most common pitfall diagnoses are needed.

Ethics

Ethics Committee Approval: Before starting the study, approval was obtained from the Institutional Review Board of University of Health Sciences Turkey, Istanbul Sancaktepe Sehit Prof. Dr. İlhan Varank Training and Research Hospital, (decision no: 113, date: 21.06.2023).

Informed Consent: Informed consent was waived due to retrospective design.

Peer-review: Externally and internally peer-reviewed.

Authorship Contributions

Concept: M.Ç.O., M.Y., Design: M.Ç.O., M.Y., Data Collection or Processing: M.Y., Analysis or Interpretation: M.Ç.O., Literature Search: M.Ç.O., M.Y., Writing: M.Ç.O.

Conflict of Interest: No conflict of interest was declared by the authors.

Financial Disclosure: The authors declared that this study received no financial support.

References

1. Cook S, Bajwa D, Hollestein L, Husain A, Rajan N. A 5-year retrospective review of skin adnexal tumours received at a tertiary dermatopathology service: implications for linked genetic diagnoses. *Br J Dermatol* 2022;186:167-173.
2. Nandyal SS, Setty SR, Puranik RB, Giriyan SS, Narayan Murthy C. Skin Adnexal Tumors: An Experience at Tertiary Care Centre. *Indian J Pathol Res Pract* 2019;8:307-316.
3. Aslan Kayıran M, Karadağ AS, Küçük Y, Çobanoğlu Şimşek B, Erdemir VA, Akdeniz N. Are clinicians successful in diagnosing cutaneous adnexal tumors? a retrospective, clinicopathological study. *Turk J Med Sci* 2020;50:832-843.
4. Sharma N, Nakra T, Agarwal S, Gupta V, Sing MK, Arava S. Cutaneous Adnexal Tumours: A Study of 395 Cases from a Tertiary Care Hospital. *Indian J Dermatol* 2023;68:41-44.
5. Pujani M, Madaan GB, Jairajpuri ZS, Jetley S, Hassan MJ, Khan S. Adnexal tumors of skin: An experience at a tertiary care center at Delhi. *Ann Med Health Sci Res* 2016;6:280-285.
6. Bartoš V. Skin appendageal tumors: A three-year dermatopathologic institutional study in Martin, Slovakia. *J Pak Assoc Dermatol* 2023;33:123-131.
7. Nair PS. A clinico-histopathological study of skin appendageal tumors. *Indian Journal of Dermatology, Venereology and Leprology* 2008;74:550.
8. Viswanathan V, Dharwadkar A, Vimal S, Bhandari P, Malhotra A, Paul B. Skin Adnexal Tumors: A study of 26 cases. *Annals of Pathology and Laboratory Medicine* 2020;7:A538-A544.
9. Zaballos P, Gómez-Martín I, Martín JM, Bañuls J. Dermoscopy of adnexal tumors. *Dermatol Clin* 2018;36:397-412.
10. Lai M, Muscianese M, Piana S, Chester J, Borsari S, Paolino G, Pellacani G, Longo C, Pampena R. Dermoscopy of cutaneous adnexal tumours: a systematic review of the literature. *J Eur Acad Dermatol Venereol* 2022;36:1524-1540.
11. Longo C, Lippolis N, Lai M, Spadafora M, Kaleci S, Condorelli AG, Lombardi M, Pampena R, Argenziano G, Nazzaro G, Scalvenzi M, Akay BN, Broganelli P, Fargnoli MC, Paoli J, Yélamos O, Pellacani G, Borsari S, Lallas A. Dermoscopic features of trichoepithelioma: A multicentre observational case-control study conducted by the International Dermoscopy Society. *J Eur Acad Dermatol Venereol*. 2023 Jun 16. Epub ahead of print.
12. Radhika K, Phaneendra BV, Rukmangadha N, Reddy MK. A study of biopsy confirmed skin adnexal tumours: experience at a tertiary care teaching hospital. *J Clin Sci Res* 2013;2:132-138.