

DOI: 10.4274/jtad.galenos.2022.70883

J Turk Acad Dermatol 2023;17(1):27-30

# COVID-19 Vaccine Induced Bullous Pemphigoid: Case Report and Review of the Literature

İ Petek Üstün<sup>1</sup>, İ Ayşegül Satılmış<sup>1</sup>, İ İlayda İş Kılıç<sup>2</sup>, İ Esra Adışen<sup>1</sup>

<sup>1</sup>Gazi University Faculty of Medicine, Department of Dermatology, Ankara, Turkey

<sup>2</sup>Gazi University Faculty of Medicine, Department of Pathology, Ankara, Turkey

## ABSTRACT

Bullous pemphigoid (BP) is a subepidermal blistering disease most commonly observed in older patients. There are some trigger factors identified such as infections, drug intake, and physical agents. The coronavirus disease-2019 (COVID-19) vaccines are a new suspected factor that may induce BP. Recently few cases of new-onset BP after vaccines were reported. We describe a 41-year-old patient who presented with bullous lesions gradually spreading to the whole body after the Pfizer COVID-19 vaccine. To identify all new-onset cases of BP after vaccination, we review the relevant literature and we found 14 previous cases reported. There are similarities between clinical and immunopathological findings in cases. After conducting a literature review, we suggest that vaccine-induced BP have a more refractory course as compared with the spontaneous occurring BP. The results of our study also support that BP may be observed more often after the mRNA syndrome-coronavirus-2 vaccine rather than the inactivated COVID-19 vaccine due to the induction of greater immune response.

**Keywords:** Bullous, Pemphigoid, COVID-19, Vaccine, New, Onset

## Introduction

Bullous pemphigoid (BP) is a common acquired autoimmune blistering disease that is observed generally in elderly individuals. It's characterized by autoantibody formation against basement membrane structural BP180 and BP230 proteins. Only less than 15% of BP patients, there are triggering factors identified such as viral infections, drug use, physical agents [1]. Rarely, there are cases triggered after influenza, tetanus, and meningococcal vaccines [2]. There are a few cases that developed after the coronavirus disease-2019 (COVID-19) vaccination. Herein, we report a patient who developed bullous pemphigoid right after the first dose of the Pfizer mRNA syndrome-coronavirus-2 (SARS-CoV-2) vaccine.

## Case Report

A 41-year-old woman visited our clinic with pruritic bullous lesions on her trunk and extremities including the palmoplantar region. The

patient had no history of infection or drug use, but the rashes began to appear 2 weeks after receiving the first dose of Pfizer mRNA SARS-CoV-2 vaccine. The patient had used high potency topical steroids (propionate of clobetasol 0.05% cream) for 3 months, but her complaints did not regress. On dermatological examination, there were widespread erythematous annular plaques and blisters on her trunk and extremities including the palmoplantar region, there was no oral mucosal involvement (Figure 1). Histopathology from a bullous lesion demonstrated subepidermal blisters accompanied by eosinophilic infiltration in the dermal-epidermal junction and superficial dermis. A direct immunofluorescence study showed the linear deposition of immunoglobulin G and C3 at the basement membrane zone (Figure 2). The patient was diagnosed with BP based on histopathological and clinical findings, and the patient was started on 1 mg/kg/day prednisolone treatment. In the 2<sup>nd</sup> week of the treatment, the patient's lesions completely resolved. The



**Address for Correspondence:** Petek Üstün Asst., Gazi University Faculty of Medicine, Department of Dermatology, Ankara, Turkey

**Phone:** +90 312 202 61 29 **E-mail:** pustun8@gmail.com **ORCID ID:** orcid.org/0000-0001-9051-8580

**Received:** 25.07.2022 **Accepted:** 09.11.2022

©Copyright 2023 by the Society of Academy of Cosmetology and Dermatology / Journal of the Turkish Academy of Dermatology published by Galenos Publishing House.

patient in this manuscript has given written informed consent to publication of her case details.

## Discussion and Review of the Literature

Although the etiopathogenesis of BP is not clear, it has been hypothesized that in genetically predisposed individuals, there is an alteration in the basement membrane by the effect of certain triggers such as burns, trauma, drug intake, and neurological diseases. It could be possible that there is a similar association between vaccination and the occurrence of BP. Vaccine-induced inflammation may induce the disease by changing the basement membrane structure followed by the production of autoantibodies targeting the basement membrane [3].

We evaluated all accessible cases of new-onset BP triggered by the COVID-19 vaccine published in the English language till the cut-off date of 22<sup>nd</sup> December 2021. A database search (Pubmed,

Google Scholar, Wiley Online Library) using the keywords ‘bullous, pemphigoid, COVID-19, vaccine, new, onset’ elicited 14 reports of new-onset BP triggered by COVID-19 vaccine. Inclusion criteria is that in the direct immunofluorescence, there needs to be IgG or C3 deposition in the basement membrane. We excluded cases that were diagnosed as BP before vaccination. No restrictions were implemented regarding patient age. A summary of the clinical and immunopathologic findings from our current case and the 14 reported cases in the literature are shown in Table 1.

Six (40%) of the patients were female and, the median age was 74.9 years (range 41-97 years). This suggests that COVID-19 vaccine-induced BP is characterized by the old age of onset as the spontaneous occurring BP. The youngest age of onset is 41 that is observed in our present case. Fourteen out of 15 patients developed the disease after the mRNA vaccine (Pfizer, Moderna, AstraZeneca 10,2,1 patients respectively). Only one patient was

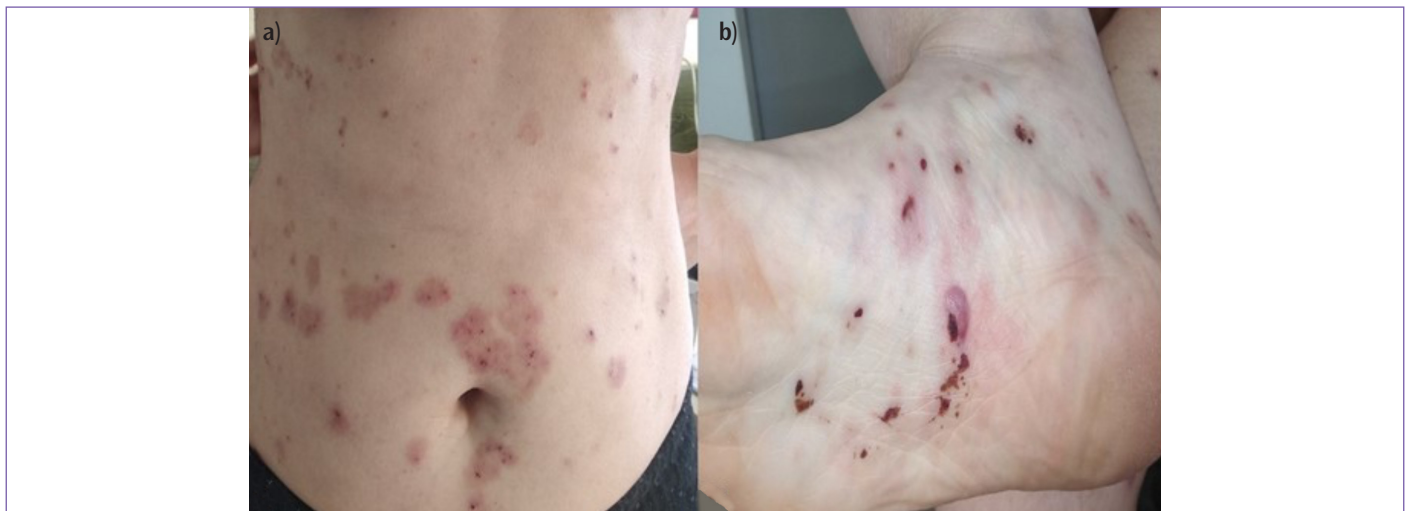
**Table 1. Clinical and immunopathologic findings in patients with new-onset bullous pemphigoid after COVID-19 vaccine**

Author	Age	Sex	Comorbidities	Vaccine-dose	Flare after 2 <sup>nd</sup> dose	Onset	DIF	Treatment	Outcome
Our case	41	Female	None	Pfizer-dose 1	X*	2w	+	OCS	2w
Nakamura et al. [2]	83	Female	Xerotic eczema	Pfizer-dose 2	-	3d	+	IVCS, IVIG	2w
Young et al. [4]	68	Male	None	Pfizer-dose 1	Flare	3w	+	TCS	3m
Agharbi et al. [5]	77	Male	None	Astrazeneca-Dose1	X*	1d	+	DCN, TCS	Favorable response**
Perez- Lopez et al. [6]	78	Female	DM, Alzheimer	Pfizer- dose1	Flare	3d	+	OCS, TCS	2w
Bostan et al. [7]	67	Male	BPH, DM*	Inactivated vaccine-dose1	Flare	5w	+	OCS, OMA	No regression
Dell’Antonia et al. [8]	83	Male	Ht	Pfizer- dose1	Flare	1w	+	OCS, TCS	3w
Tomayko et al. [9]	97	Female	Psoriasis	pfizer- dose2	-	2d	+	DCN, NAM, TCS	2w
Tomayko et al. [9]	75	Male	Eczema	Pfizer-dose2	-	10d	+	OCS, NAM, DCN, TCS	3w
Tomayko et al. [9]	64	Male	None	Pfizer- dose2	-	14d	+	TCS	4w
Tomayko et al. [9]	82	Male	Eczema	Pfizer- dose2	-	1d	+	TCS	2w
Tomayko et al. [9]	95	Female	Nonmelanoma skin cancer	Pfizer-dose1	No flare	5d	+	NAM, DCN, TCS	8w
Tomayko et al. [9]	87	Male	Stasis dermatitis, Alzheimer disease	Moderna-Dose2	-	21d	+	OCS, NAM, DCN	No regression
Tomayko et al. [9]	42	Female	Hand eczema	Moderna-Dose2	-	3d	+	IVCS, IMCS, TCS	No regression
Tomayko et al. [9]	85	Male	Dementia	Pfizer-dose1	No flare	5d	+	OCS	No regression

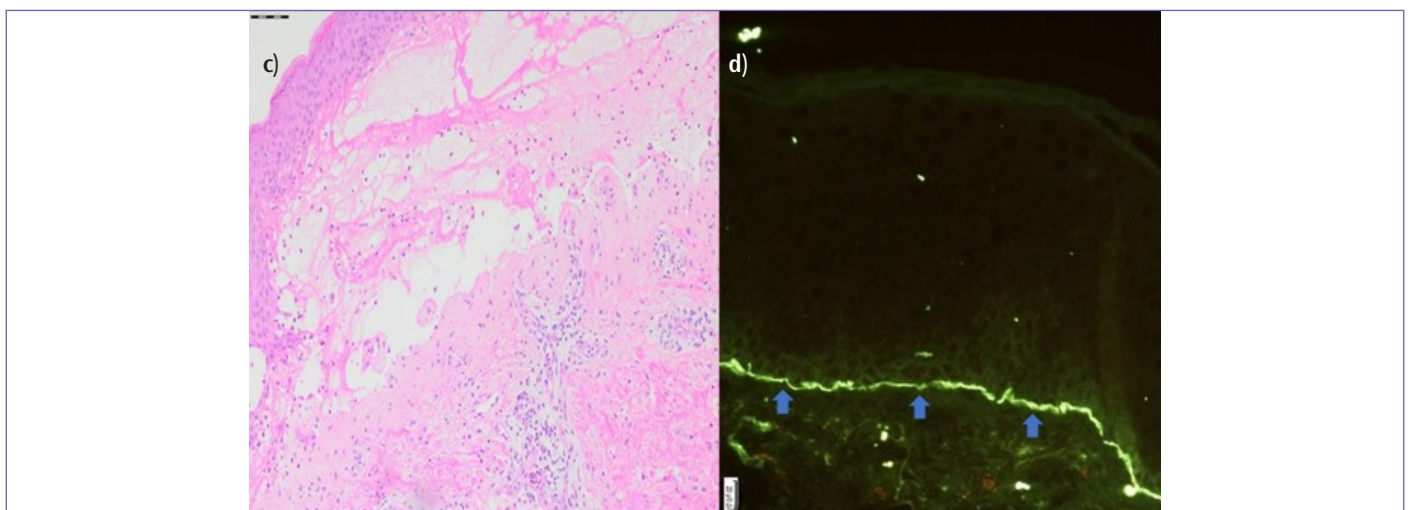
\*This patient was using vildagliptin for diabetes mellitus, \*\*The patient was treated by high potency topical corticosteroid and systemic doxycycline. Favorable outcome was reported but full response time is unknown, X: \*The patient didn't receive the 2<sup>nd</sup> dose of COVID-19 vaccine. DIF: Direct immunofluorescence, DM: Diabetes mellitus, BPH: Benign prostate hyperplasia d:days, w:weeks, m: months OCS: Oral corticosteroid, IVCS: Intravenous corticosteroid, IMCS: Intramuscular corticosteroid, IVIG: Intravenous immunoglobulin, TCS: Topical corticosteroid, DCN: Doxycycline, NAM: Nicotinamide OMA: Omalizumab

reported whose diagnosis of BP was confirmed after the inactivated COVID-19 vaccine. In this patient, prolonged use of vildagliptin for diabetes mellitus was thought as the cause of the refractory course of the disease [7]. These observations raise the question of why BP is observed more often after the mRNA vaccine rather than the inactivated vaccine. Talotta [10] hypothesized that the COVID-19 mRNA vaccine increases the risk of autoimmunity by activating endosomal pattern recognition receptors, producing cross-reactive autoantibodies. Moreover, the generation of type 1 IFN response may cause the disruption of immunological self-tolerance and, therefore, trigger autoimmunity. These findings remind us of a significant question of whether BP is induced by an adjuvant of the vaccine itself and is there any association between the high level of autoantibodies and the development of BP. In a study by Lim

et al. [11], it was shown that there were higher concentrations of neutralizing antibodies against SARS-CoV-2 in patients who received mRNA vaccine than in those who received the inactivated COVID-19 vaccine. These results support that compared with the inactivated vaccine, the mRNA vaccine may trigger a greater immune response. In eight patients (53.3%), the rashes appeared after the first dose of vaccine, while seven (46.6%) patients developed the disease after the second dose. Of the 8 patients who developed the rashes after the first vaccine, 6 of them received the booster dose of COVID-19 vaccine. Four (66.6%) of 6 patients experienced a flare-up of blisters. Two (33.3%) of 6 patients tolerated the second dose and had no worsening of the disease. Tomayko et al. [9] hypothesized that rapid onset of rash after the first dose of vaccine may be related to exacerbation of a preexisting subclinical autoreactivity by temporary



**Figure 1.** Clinical images, a) Excoriated annular plaques on anterior trunk, b) excoriated papules on erythematous base and a blister on right plantar region



**Figure 2.** Histopathological images, c) Subepidermal bulla formation with eosinophil infiltration in the dermal-epidermal junction, (H&E stain X100), d) Linear deposition of IgG noted on direct immunofluorescence as indicated by the blue arrows

activation of the immune system by vaccines. Also, the longer the time between vaccination and the onset of the disease, the less likely the patient would have subclinical autoantibodies. According to our review, there is no correlation between rapid disease onset and the flare-up of the disease after the second dose of the vaccine. The latency between vaccine and disease onset and the existence of subclinical autoantibodies remains to be proven.

Including the present case, the median latency period between vaccine application and the appearance of the symptoms is 9, 8 days. In recent studies, the latency period was reported between 1 day to 1 month in influenza vaccine-induced disease onset [3]. In our study the longest latency period, 5 weeks, is observed after the inactivated COVID-19 vaccine. This is a quite remarkable finding and needs to be elucidated. Histopathology was similar in all patients and direct immunofluorescence was IgG or C3 positive in all cases. In 11 (73.3%) out of 15 patients had a considerable clinical response with different therapy modalities (range 2 to 12 weeks). However, in four patients, there was a failure to control disease activity and new blisters continued to develop. Among the 11 patients who showed a significant response to the treatment, 3 patients (27.2%) were treated by high potency topical steroids alone and 8 patients (72.7%) had improvement in clinical findings with systemic treatment (combinations of topical and systemic corticosteroids, doxycycline, nicotinamide, omalizumab, intravenous immunoglobulin therapy). In a single-center retrospective study which included 96 BP patients with a mean age of 84 years, while 62% of patients had resolution of blisters with topical steroid alone, 25% of patients had additional systemic treatment due to failure of treatment or relapses [12]. In contrary to this study, a higher percentage of patients needed further systemic therapy to control the disease in our study. It's conceivable that vaccine-induced BP is more likely to have a refractory course as compared with the spontaneous occurring BP. Therefore, these patients should be closely followed up.

## Conclusion

Recently, few cases of BP after COVID-19 vaccination were reported. By reporting the cases, new side effects can be recognized and the frequency of side effects can be determined and included in the prospectus information. The accumulating evidence suggests that vaccine-induced BP is more resistant to treatment than spontaneous BP and long-term follow-up of patients is required. The COVID-19 vaccine has been newly used in humans and with the increase of our knowledge about different types of vaccines, personalized vaccine dosing or schedules may be developed in the future.

## Ethics

**Informed Consent:** The patient in this manuscript has given written informed consent to publication of her case details.

**Peer-review:** Internally peer-reviewed.

## Authorship Contributions

Surgical and Medical Practices: E.A., Concept: A.S., İ.İ.K., E.A., Design: P.Ü., E.A., Data Collection or Processing: P.Ü., A.S., Analysis or Interpretation: P.Ü., İ.İ.K., Literature Search: P.Ü., A.S., Writing: P.Ü.

**Conflict of Interest:** No conflict of interest was declared by the authors.

**Financial Disclosure:** The authors declared that this study received no financial support.

## References

- Lo Schiavo A, Ruocco E, Brancaccio G, Caccavale S, Ruocco V, Wolf R. Bullous pemphigoid: etiology, pathogenesis, and inducing factors: facts and controversies. *Clin Dermatol* 2013;31:391-399.
- Nakamura K, Kosano M, Sakai Y, Saito N, Takazawa Y, Omodaka T, Kuniwa Y, Okuyama R. Case of bullous pemphigoid following coronavirus disease 2019 vaccination. *J Dermatol* 2021;48:e606-e607.
- Walmsley N, Hampton P. Bullous pemphigoid triggered by swine flu vaccination: case report and review of vaccine triggered pemphigoid. *J Dermatol Case Rep* 2011;5:74-76.
- Young J, Mercieca L, Ceci M, Pisani D, Betts A, Boffa MJ. A case of bullous pemphigoid after the SARS-CoV-2 mRNA vaccine. *J Eur Acad Dermatol Venereol* 2022;36:e13-e16.
- Agharbi FZ, Eljazouly M, Basri G, Faik M, Benkirane A, Albouzi A, Chiheb S. Bullous pemphigoid induced by the AstraZeneca COVID-19 vaccine. *Ann Dermatol Venereol* 2022;149:56-57.
- Pérez-López I, Moyano-Bueno D, Ruiz-Villaverde R. Bullous pemphigoid and COVID-19 vaccine. *Med Clin (Barc)* 2021;157:e333-e334.
- Bostan E, Yel B, Akdogan N, Gokoz O. New-onset bullous pemphigoid after inactivated Covid-19 vaccine: Synergistic effect of the Covid-19 vaccine and vildagliptin. *Dermatol Ther* 2022;35:e15241.
- Dell'Antonia M, Anedda S, Usai F, Atzori L, Ferrelli C. Bullous pemphigoid triggered by COVID-19 vaccine: Rapid resolution with corticosteroid therapy. *Dermatol Ther* 2022;35:e15208.
- Tomayko MM, Damsky W, Fathy R, McMahon DE, Turner N, Valentin MN, Rallis T, Aivaz O, Fox LP, Freeman EE. Subepidermal blistering eruptions, including bullous pemphigoid, following COVID-19 vaccination. *J Allergy Clin Immunol* 2021;148:750-751.
- Talotta R. Do COVID-19 RNA-based vaccines put at risk of immune-mediated diseases? In reply to "potential antigenic cross-reactivity between SARS-CoV-2 and human tissue with a possible link to an increase in autoimmune diseases". *Clin Immunol* 2021;224:108665.
- Lim WW, Mak L, Leung GM, Cowling BJ, Peiris M. Comparative immunogenicity of mRNA and inactivated vaccines against COVID-19. *Lancet Microbe* 2021;2:e423.
- Ing Ingen-Housz-Oro S, Valeyrie-Allanore L, Ortonne N, Roujeau JC, Wolkenstein P, Chosidow O. Management of bullous pemphigoid with topical steroids in the clinical practice of a single center: outcome at 6 and 12 months. *Dermatology* 2011;222:176-179.