

DOI: 10.4274/jtad.galenos.2021.25733

J Turk Acad Dermatol 2022;16(4):104-107

Hand-Foot Skin Reaction by Sorafenib

Devansi Sarawgi, Madhumita Das, Subhasmita Baisya, Sumit Sen

West Bengal University of Health Sciences, IPGMER-SSKM Hospital, Clinic of Dermatology, Kolkata, India

ABSTRACT

Hand-foot skin reaction (HFSR) is a dose dependent adverse drug reaction of chemotherapeutic drugs like sorafenib, sunitinib etc. It usually presents as painful erythematous lesions over pressure bearing and trauma prone areas of the body, with varying degree of dysesthesia, callosity and blistering. Sorafenib is a multi-kinase inhibitor which is used as an anticancer agent in the treatment of inoperable hepatocellular carcinoma, advanced renal cell carcinoma etc. It is usually well-tolerated but development of HFSR can hamper its long-term usage. HFSR can be debilitating to the patient hence prompt diagnosis is essential for its management. However due to limited usage of sorafenib in our country, existing knowledge about the presentation of HFSR in Indian population is sparse and is mostly based on case reported from western countries. Here we report a case of HFSR occurring in a known patient of gastrointestinal stromal tumor following sorafenib therapy.

Keywords: Sorafenib, Hand-foot skin reaction, Adverse drug reaction

Introduction

Hand-foot skin reaction (HFSR) is a dose dependent adverse cutaneous reaction of chemotherapeutic agents like Sorafenib, Sunitinib etc [1]. Localized involvement of pressure bearing parts and trauma prone areas of body like heels, finger pads, ball of great toe is a key feature of HFSR. Various forms of presentation include dysesthesia, painful erythematous plaques with varying degree of blistering, callosities, macular hyperpigmentation [2]. It should not be confused with Hand-Foot Syndrome caused by drugs like capecitabine, cytarabine which manifest as diffuse redness and swelling of palmpoplantar region [1].

Sorafenib is a multi-kinase inhibitor which is food and drug administration approved for the treatment of inoperable hepatocellular carcinoma, advanced renal cell carcinoma and radioactive iodine resistant thyroid carcinoma [3]. Off-labelled

uses include gastrointestinal stromal tumour (GIST), angiosarcoma [4]. It is relatively well-tolerated though development of moderate to severe HFSR can hamper its long-term use in some patients [3]. Limited number of cases of HFSR due to sorafenib have been reported from India till date. Here we report one such case of HFSR occurring in a patient of GIST on sorafenib therapy.

Case Report

A 48-year-old man presented to our out patient department with complaint of tingling sensation along with painful eruption on his palms and soles for last 3 weeks. He was a known case of GIST. Four years back, he underwent oesophago-gastric anastomosis and was started on imatinib. He experienced no significant adverse reaction while on imatinib therapy. However, due to recurrence of tumour at anastomosis site, he was switched to tab sorafenib 400



Address for Correspondence: Devansi Sarawgi MD, West Bengal University of Health Sciences, IPGMER-SSKM Hospital, Clinic of Dermatology, Kolkata, India
Phone: +919875644004 **E-mail:** devansi.sarawgi@gmail.com **ORCID ID:** orcid.org/0000-0002-2593-0533
Received: 21.04.2021 **Accepted:** 06.06.2021

©Copyright 2022 by the Society of Academy of Cosmetology and Dermatology / Journal of the Turkish Academy of Dermatology published by Galenos Publishing House.

mg twice daily last month. Within 10 days of initiating sorafenib, he was distressed to find painful hyperpigmented lesions with some blisters on his hands and feet. He promptly consulted his oncologist regarding the same who then referred him to our department for opinion. On examination, tender erythematous plaques were found over the knuckles and around the base of the thumbs. Yellowish hyperkeratotic callous-like lesions were seen on the under-surface of the right great toe and heels (Figure 1). No other muco-cutaneous sites were involved. Routine blood investigations were within normal limits. On histopathological examination, marked hyperkeratosis, ectatic blood vessels in papillary dermis and perivascular lymphomononuclear infiltration were seen (Figure 2). Temporal association of oral sorafenib intake with appearance of clinical features, along with histopathological findings led us to the diagnosis of sorafenib induced HFSR. Severity of HFSR in our patient was grade 2, according to National Cancer Institute common terminology criteria for adverse event grading system. With score of 7 on Naranjo adverse drug reaction probability scale, association between sorafenib and HFSR in our case was found to be 'probable'. Patient was advised to discontinue sorafenib therapy and was

prescribed emollient cream and mometasone ointment once daily application. After 3 weeks, subjective improvement was reported by the patient and his lesions regressed considerably (Figure 3). Informed consent was taken from the patient for possible case report publication.

Discussion

Sorafenib is a novel small molecule which is widely used as an anticancer agent. It directly prevents proliferation of cancer cells by inhibiting Raf/MEK/ERK pathway and also blocks tumour blood supply by targeting vascular endothelial growth factor receptor (VEGFR)-2, VEGFR-3 and platelet-derived growth factors receptors (PDGFR) [2]. Dermatological side-effects like acne, hair loss, flushing, HFSR, desquamation etc is seen in approximately 90% patients [5]. In one case series, HFSR was reported in 78% of patients receiving sorafenib. Among them, 11% had grade 1 HFSR while grade 2 and 3 were found in 33% each [6]. Risk factors of HFSR include female gender, tumour type, liver metastasis, normal pre-treatment white cell count etc. [7]. HFSR usually develop within first six weeks of initiating treatment [3]. In one study, mean duration of onset

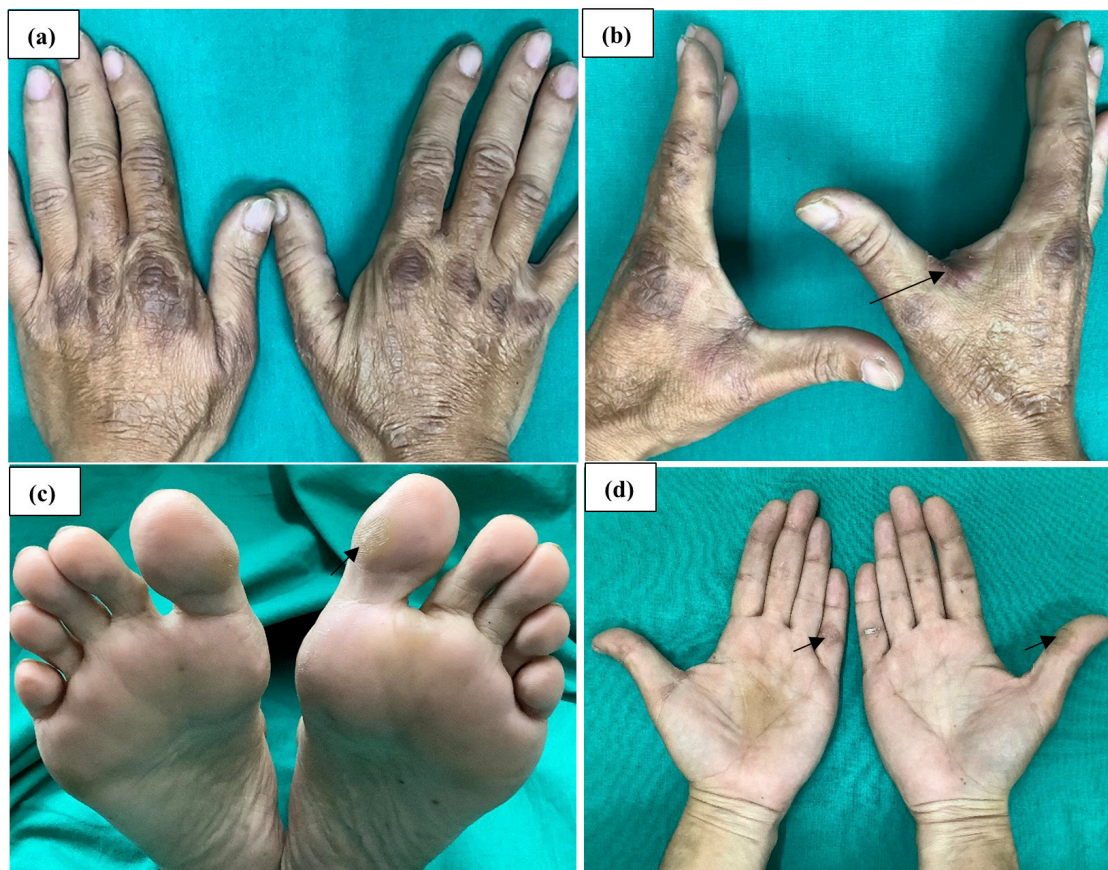

Figure 1. Erythematous plaques over the knuckles (a), and around base of the thumb (b). Callosity on the great toe (c) and hand (d)

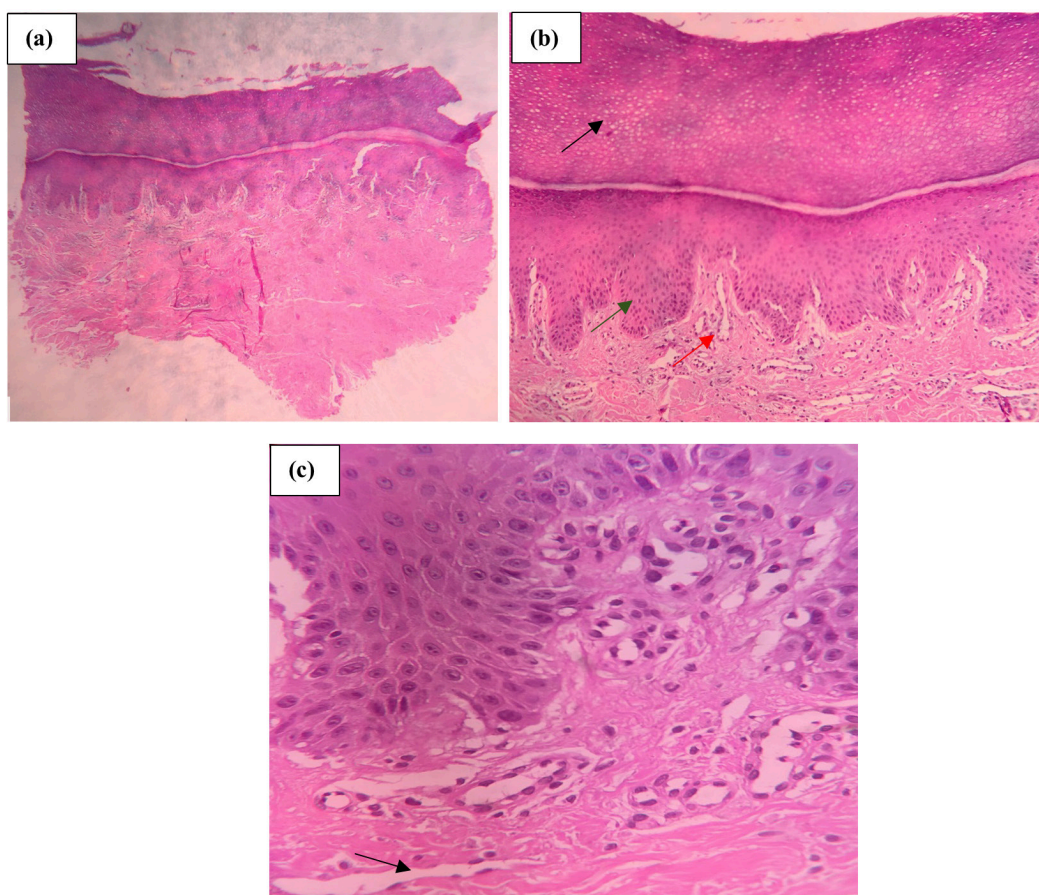


Figure 2. Biopsy revealed marked orthokeratosis [black arrow in (b)], acanthosis [green arrow in (b)], numerous dilated blood vessels [red arrow in (b) and black arrow in (c)] along with mild perivascular lymphocytic in hematoxylin and eosin stain

was found to be around 15 days [6]. Presenting feature includes symmetrical erythematous lesions on acral sites, sometimes with excoriations and blistering. Differential diagnosis include hand-foot syndrome, graft-versus-host disease, porphyria cutanea tarda and contact dermatitis [2]. In hand-foot syndrome diffuse involvement is usually seen and palms are more frequently involved than soles while in hand-foot skin reaction, localized lesions on pressure and/or trauma prone sites are present and soles are involved more often than palms [7]. Pathogenesis is not well known. One explanation of localized pattern of involvement is impaired vascular repair process due to inhibition of VEGFR and PDGFR thereby making blood vessels on pressure and trauma prone sites more vulnerable to sorafenib leakage and toxicity [2]. Direct cytotoxic effect of sorafenib in eccrine gland is another proposed theory [5]. Two cases with lesions identical to HFSR on sites other than palmoplantar region like elbows, old scar etc. were reported and its author hypothesised sorafenib induced

HFSR to be a Koebner phenomenon [1]. Lesions are typically painful and may even be debilitating, thereby warranting dose reduction or cessation of therapy [3]. Most frequently, sorafenib at the standard dose (400 mg BD) is most commonly found to trigger HFSR, however in one case report, sorafenib at even low dose (200 mg BD) led to development of HFSR [8]. Due to its profound effect on the quality of life, patients should be counselled regarding the possibility of HFSR development before initiating the known culprit chemotherapeutic agents [7].

HFSR is considered to be a common adverse effect of sorafenib therapy in the western world. However due to its limited usage in our country, existing knowledge of this cutaneous side effect among Indian physicians is sparse and mostly based on cases reported from western countries. Awareness regarding its clinical presentation among the dermatologists is required for proper diagnosis and timely management of this debilitating drug reaction.

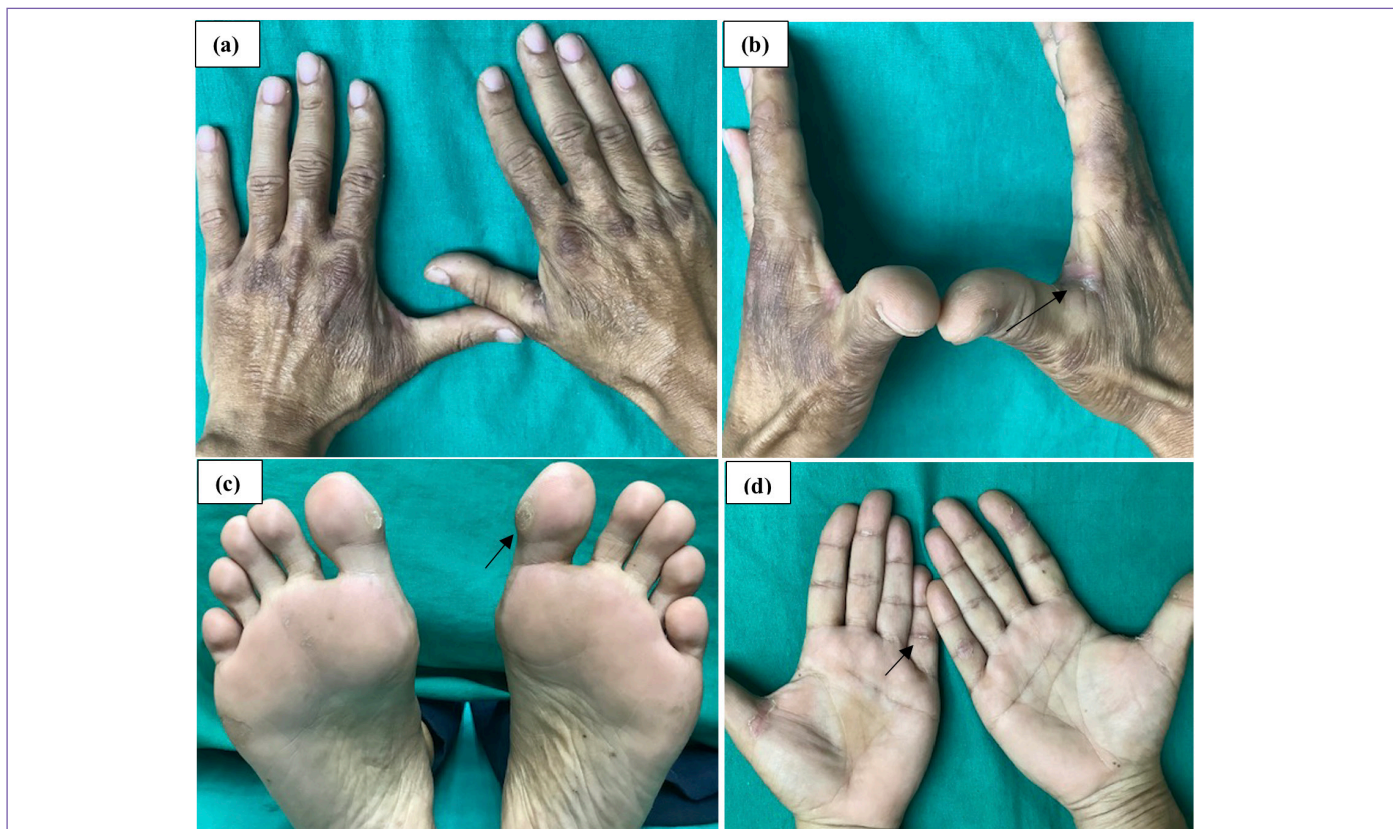

Figure 3. After 3 weeks of stopping sorafenib therapy and mometasone once daily application, decrease in erythema [shown by arrow on (b)] and reduced size of callosity [shown by arrow on (c) and (d)] was noted

Ethics

Informed Consent: Informed consent was taken from the patient for possible case report publication.

Peer-review: Externally peer-reviewed.

Authorship Contributions

Surgical and Medical Practices: D.S., M.D., S.B., S.S., Concept: D.S., M.D., S.B., S.S., Data Collection or Processing: D.S., M.D., S.B., Analysis or Interpretation: D.S., M.D., S.B., S.S., Literature Search: D.S., M.D., Writing: D.S., M.D., S.B., S.S.

Conflict of Interest: No conflict of interest was declared by the authors.

Financial Disclosure: The authors declared that this study received no financial support.

References

1. Sibaud V, Delord JP, Chevreau C. Sorafenib-induced hand-foot skin reaction: A Koebner phenomenon? *Target Oncol* 2009;4:307-310.
2. Lipworth AD, Robert C, Zhu AX. Hand-Foot Syndrome (Hand-Foot Skin Reaction, Palmar-Plantar Erythrodysesthesia): Focus on Sorafenib and Sunitinib. *Oncology* 2009;77:257-271.
3. Ai L, Xu Z, Yang B, He Q, Luo P. Sorafenib-associated hand-foot skin reaction: practical advice on diagnosis, mechanism, prevention, and management. *Expert Rev Clin Pharmacol* 2019;12:1121-1127.
4. Montemurro M, Gelderblom H, Bitz U, Schütte J, Blay JY, Joensuu H, Trent J, Bauer S, Rutkowski P, Duffaud F, Pink D. Sorafenib as third- or fourth-line treatment of advanced gastrointestinal stromal tumour and pretreatment including both imatinib and sunitinib, and nilotinib: A retrospective analysis. *Eur J Cancer* 2013;49:1027-1031.
5. McLellan B, Kerr H. Cutaneous toxicities of the multikinase inhibitors sorafenib and sunitinib. *Dermatol Ther* 2011;24:396-400.
6. Yang CH, Lin WC, Chuang CK, Chang YC, Pang ST, Lin YC, Kuo TT, Hsieh JJ, Chang JW. Hand-foot skin reaction in patients treated with sorafenib: a clinicopathological study of cutaneous manifestations due to multitargeted kinase inhibitor therapy. *Br J Dermatol* 2008;158:592-596.
7. Demirdag HG, Ayanoglu BT, Armagan BY. Evaluation of hand-foot syndrome and hand-foot skin reaction: Case series. *Turkderm-Turk Arch Dermatol Venereology* 2019;53:28-31.
8. Shah VH, Supekar BB, Singh RP, Mukhi JI. Sorafenib induced handfoot skin reaction at low dose. *Indian Dermatol Online J* 2020;11:997-1000.