

Primary Localized Cutaneous Nodular Amyloidosis Presenting Bilaterally on the Nose: A Successful Response to Cryotherapy

Hasan Tak,^{1*} MD, Nazlı Dizen Namdar,¹ MD, Gülben Sarıcı,¹ MD, Mehtap Kızır,¹ MD, Mehmet Hüseyin Metineren,² MD

Address: ¹Dermatology Department, ²Pathology Department, University of Dumlupınar, Medical Faculty, Kütahya, Turkey

E-mail: htak70@yahoo.com

*Corresponding Author: Dr. Hasan Tak, University of Dumlupınar, Medical Faculty, Kutahya, Turkey

Published:

J Turk Acad Dermatol 2017; **11** (1): 17111c6

This article is available from: <http://www.jtad.org/2017/1/jtad17111c6.pdf>

Keywords: Amyloidosis, cutaneous nodular amyloidosis, cryotherapy

Abstract

Observation: Amyloidosis represents a group of diseases characterized by amyloid deposition, which may trigger dysfunction in several organs, including the skin. Amyloidosis can be classified as either systemic or cutaneous; both primary and secondary forms can occur. Primary localized cutaneous nodular amyloidosis (PLCNA) is the rarest cutaneous presentation of amyloidosis. Treatment of PLCNA is difficult. The rate of local recurrence is high after all forms of treatment. We present the case of a 38-year-old Turkish male with PLCNA, which developed on both sides of the nose. Cryotherapy was successful.

Introduction

Amyloidosis is a generic term used to describe a group of diseases characterized by deposition of a substance composed chiefly of a fibrous protein, termed amyloid, which may compress, and/or cause dysfunction of, several organs, including the skin [1,2]. Amyloidosis can be classified as either systemic or cutaneous; both primary and secondary forms are known [3,4].

Primary localized cutaneous nodular amyloidosis (PLCNA) is characterized by amyloid deposition in previously healthy skin, with no systemic involvement, and is usually classified into one of three major forms: lichen amyloidosis (the

commonest type), macular amyloidosis, and a rare nodular form of amyloidosis [3,4].

Primary localized cutaneous nodular amyloidosis (PLCNA) occurs to equal extents in both sexes, usually in adults; the mean age at diagnosis is 60.8 years. The mean duration of lesions at the time of diagnosis is 13.5 years [5]. Patients present with asymptomatic nodules or plaques that are single or multiple; rose-brown in color; and that tend to involve the face (principally the nose and periauricular areas), the genitals, and the trunk and limbs. The lesions are similar to those found in cases of primary systemic amyloidosis associated with lymphoproliferative plasmacytic disease [1].

Herein, we present the case of a 38-year-old Turkish male with PLCNA, which developed on

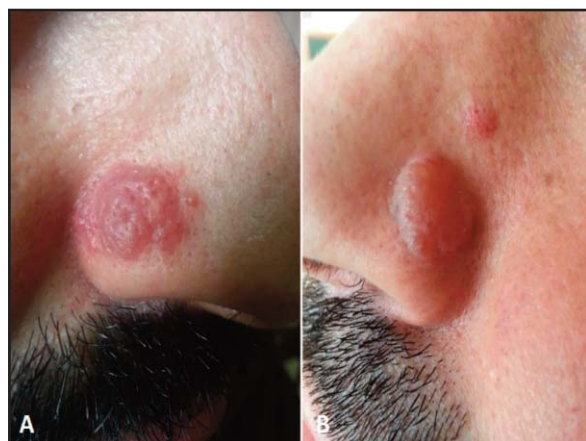

Figure 1. (A) Erythematous nodule on the right side of the nose. (B) Erythematous nodule and satellit papule on the left side of the nose

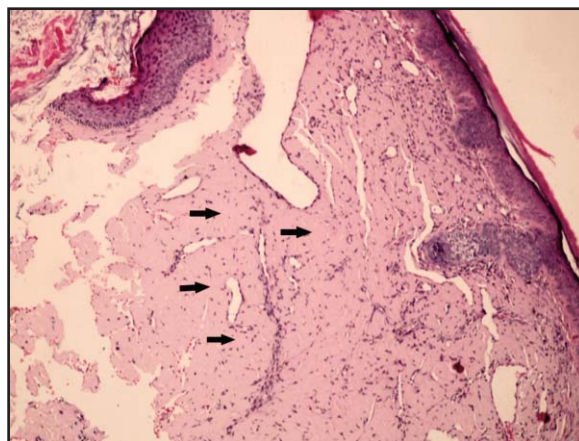


Figure 2. Photomicrograph of the biopsy showing deposition of pale eosinophilic amorphous material throughout the entire dermis (arrow; hematoxylin and eosin stain x 100)

both sides of the nose, and that was successfully treated with cryotherapy.

Case Report

A male patient aged 38 years presented with rubescent nodules distributed symmetrically on both sides of the nose; the nodules had developed 2 years prior. He had no other subjective complaint. Dermatological examination revealed two 1.8 × 1.8-cm-sized, well-demarcated, firm, erythematous nodular lesions, one on either side of the nose. A 0.4 × 0.4-cm-sized erythematous satellite lesion was also apparent superior to the lesion on the left side of the nose (**Figure 1**). A cutaneous punch biopsy (4-mm diameter) was performed on the nodule of the left side of the nose. Histopathological examination revealed extensive deposition of pale eosinophilic amorphous material throughout the entire dermis, with a dense infiltration of plasma cells (**Figure 2**). Also, amyloid deposition was evident over the entire dermis; the tissue stained strongly with crystal violet (**Figure 3**).

Laboratory data were normal in terms of the complete blood cell count, urinalysis, liver and renal function tests, blood glucose levels, lipid panel, and the erythrocyte sedimentation rate. Also, serum protein electrophoresis and chest radiography were normal. We found no systemic manifestation of amyloidosis (macroglossia or organomegaly).

We diagnosed PLCNA based on the clinical, histopathological, and laboratory findings.

Discussion

Primary localized cutaneous nodular amyloidosis is the rarest cutaneous presentation of

amyloidosis. The condition is characterized by diffuse deposition of amyloids in the dermis per se, subcutaneous tissue, and small vessels of the dermis [2, 5]. In addition, a perivascular infiltrate of plasma cells may be evident [1, 2]. The pathogenesis of the condition is not fully understood, but the presence of monoclonal light chain immunoglobulin synthesized by plasma cells may indicate local dysfunction of such cells [6, 7].

Studies of gene rearrangement in a number of patients have identified clones of amyloid-producing plasma cells in nodular lesions of the skin, with no signs of clonal proliferation of plasma cells in the bone marrow [8].

The clinical differential diagnosis of PLCNA requires consideration of entities including lymphoma cutis, pseudolymphoma, pretibial myxedema, cutaneous sarcoidosis, granuloma annulare, granuloma faciale, reticulohistiocytoma, and multicentric reticulohistiocytosis. However, these diseases can be easily distinguished histopathologically [2].

Treatment of PLCNA is difficult; the rate of local recurrence is high after all forms of treatment. Therapeutic modalities that have been used to improve the appearance of lesions include cryotherapy, electrodesiccation with curettage, intralesional steroid injections, dermabrasion, surgical excision with or without split skin grafting, and (more re-

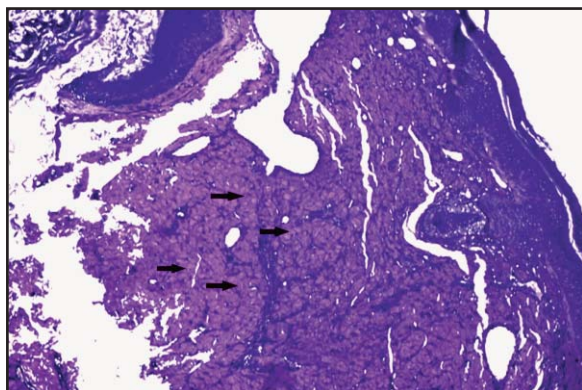


Figure 3. Photomicrograph of the biopsy showing purple-violet colored diffuse amyloid deposition over the entire dermis (arrow; Crystal Violet stain x 100)

cently) carbon dioxide and pulsed dye laser therapy [9,10].

Cryotherapy with liquid nitrogen is one of the most common treatments. This treatment is easy to perform, can be done in the medical office, is not associated with bleeding, may not require anesthesia, and yields good results. Nitrogen is sprayed directly onto the lesion through a cryospray or catheter, or may be swabbed on. When liquid nitrogen comes into contact with the skin, the temperature drops to -196°C . The skin may be frozen to a depth of 10 mm, depending on the duration of application and the distance travelled by the spray [11,12].

Our patient had previously been offered surgical excision, but declined. We performed cryotherapy (nitrogen spraying; three sprays at each visit) biweekly in our clinic. Six sessions afforded complete recovery of the lesions, with subsequent gentle scarring (Figures 4 and 5).

Rapid freezing causes cell death and tissue necrosis. Collagen fibers and cartilage are resistant to freezing, which is of paramount concern when cicatrization is required [13].

If cryotherapy is planned, it is necessary to consider the size and type of the lesion, the lesional site, and whether the lesion is recurrent. Cryotherapy is contraindicated for poorly delimited and cicatricial lesions, for patients suffering from urticaria, and for those who are intolerant to cold (such as patients with Raynaud's disease) [11,12]. Our patient did not have urticaria or cold-intolerance.

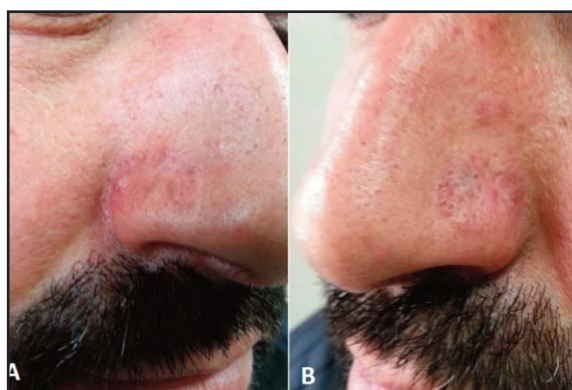

Figure 4. (A) Appearance of the right side of the nose after cryotherapy. (B) Appearance of the left side of the nose after cryotherapy

Although progression of PLCNA to systemic amyloidosis has been reported, most patients with PCNA do not exhibit such progression and remain in good general health, particularly if no clinical or laboratory evidence of systemic disease is apparent at the time of diagnosis [14].

The rates of progression of PLCNA to systemic amyloidosis were 7–50% in some case series. Thus, PLCNA patients should be followed-up long-term [14]. *Kaltoft et al.* reviewed the literature and found that the risk of local recurrence was 9%, predominantly in males with facial lesions [15]. No correlation was evident between the type of treatment given and the risk of local recurrence. Our patient was male and had a facial lesion. Neither recurrence nor systemic involvement was evident at his 1-year follow-up.

PLCNA is a rare skin disease and the recurrence rate is high after all forms of treatment. In the present report, we show that PLCNA responds well to cryotherapy. Thus, cryotherapy may be considered for patients with PLCNA, either as a first option, or when surgery and other treatments cannot be implemented.

References

1. Breathnach S. Amyloid and the amyloidosis of the skin. In: Burns T, Breathnach S, Cox N, Griffiths C, editors. *Rook's Textbook of Dermatology*. 8th ed. Oxford: Blackwell Publishing Ltd; 2010, 42-59.
2. Groves R, Black M. Amyloidosis. In: Bologna JL, Jorizzo JL, Schaffer JV, editors. *Dermatology*. Vol 2. 3th ed. Philadelphia: WB Saunders Publishing; 2012, 699-708.

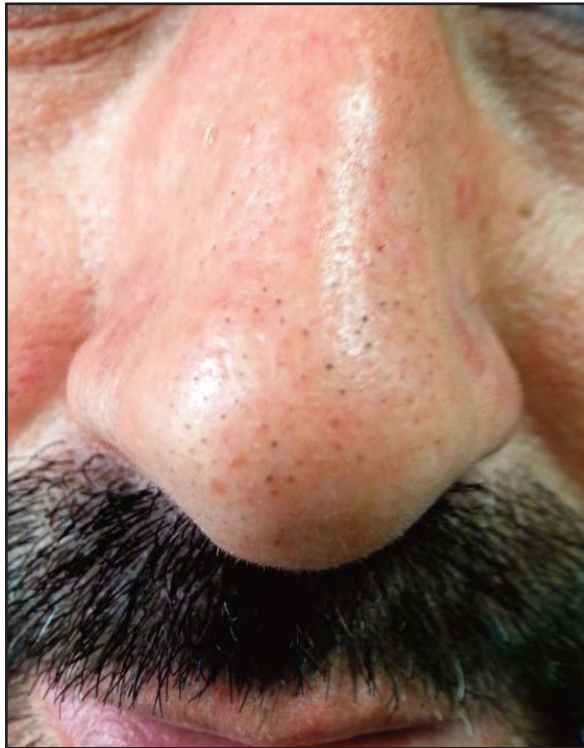


Figure 5. Front view of the nose of the patient after cryotherapy

3. Borowicz J, Gillespie M, Miller R. Cutaneous amyloidosis. *Skinmed* 2011; 9: 96-100. PMID: 21548513
4. Schreml S, Szeimies RM, Vogt T, Landthaler M, Schroeder J, Babilas P. Cutaneous amyloidoses and systemic amyloidoses with cutaneous involvement. *Eur J Dermatol* 2010; 20: 152-160. PMID:20071301
5. Tarun N, Sunil D, Sanjeev H, Bishan Dass R. Nodule in the nasolabial fold. *Indian J Dermatol Venereol Leprol* 2008; 74: 299. PMID:18595199
6. Borowicz J, Shama L, Miller R. Nodular cutaneous amyloidosis. *Skin* 2011; 9: 316-318. PMID: 22165048
7. Hagari Y, Mihara M, Konohana I, Ueki H , Yamamoto O, Koizumi, H. Nodular localized cutaneous amyloidosis: further demonstration of monoclonality of infiltration plasma cells in four additional Japanese patients. *Br J Dermatol* 1998; 138: 652-654. PMID: 9640373
8. Grunewald K, Sepp N, Weyrer K, et al. Gene rearrangement studies in the diagnosis of primary systemic and nodular primary localized cutaneous amyloidosis. *J Invest Dermatol* 1991; 97: 693-696. PMID: 1940440
9. Bozikov K, Janezic T. Excision and split thickness skin grafting in the treatment of nodular primary localized cutaneous amyloidosis. *Eur J Dermatol* 2006; 16: 315-316. PMID: 16709507
10. Alster TS, Manaloto RM. Nodular amyloidosis treated with a pulsed dye laser. *Dermatol Surg* 1999; 25: 133-135. PMID: 10037520
11. Martin G. The impact of the current United States guidelines on the management of actinic keratoses: is it time for an update? *J Clin Aesthet Dermatol* 2010; 3: 20-25. PMID: 21103312
12. Kuflik EG, Gage AA. *Cryobiology. Cryosurgical treatment for skin cancer.* New York, Igaku-shoin, 1990, 266.
13. Dawber R, Colver G, Jackson A. *Criocirurgia cutânea - Princípios e prática clínica.* São Paulo: Manole; 1999, 135.
14. Woolons A, Black MM. Nodular localized primary cutaneous amyloidosis: a long-term follow-up study. *Br J Dermatol* 2001; 145: 105-109. PMID: 11453916
15. Kaltoft B, Schmidt G, Lauritzen AF, Gimsing P. Primary localised cutaneous amyloidosis--a systematic review. *Dan Med J.* 2013; 60: A4727 PMID: 24192243