

Secondary Skin Hyperpigmentation During with Peginterferon Alpha and Ribavirin Treatment for Chronic Hepatitis C Virus Infection: Case Report

Havva Yıldız Seçkin,^{1*} MD, Akgül Arıcı,² MD, Yalçın Baş,¹ MD, Zennure Takçı,¹ MD, Sercan Sezgin,¹ MD

Address: ¹Gaziosmanpaşa University, School of Medicine, Department of Dermatology, ²Department of Pathology, Tokat

E-mail: havvayildiz1982@mynet.com

* Corresponding Author: Dr. Havva Yıldız Seçkin, Gaziosmanpaşa University School of Medicine, Department of Dermatology 60100 Tokat, Turkey

Published:

J Turk Acad Dermatol 2016; 10 (1): 16101c1

This article is available from: <http://www.jtad.org/2016/1/jtad16101c1.pdf>

Keywords: HCV infection, hyperpigmentation, peginterferonalpha-2a

Abstract

Observation: Interferon-alpha (INF) or peginterferon alpha (PEG INF) and ribavirin combination therapy in chronic hepatitis C virus (HCV) infection is recognized as an effective treatment method. Skin related side effects have rarely been reported during chronic HCV infection treatments and they usually are lesions seen in the local injection sites. We present a case with HCV infection that occurred in the sun-exposed areas and axillar area by secondary pigmentation during PEG-INF-2a plus and ribavirin combination therapy.

Introduction

Chronic hepatitis C virus (HCV) infections are known to be associated with various skin diseases. Among the most common diseases are lichen planus, porphyria cutanea tarda, chronic pruritus, and cutaneous necrotizing vasculitis [1,2]. Moreover, rarely variety of skin lesions are developed during interferon alpha (INF) or peginterferon alpha (PEGINF) with combined ribavirin treatments. Injection site reaction, generalized skin rashes, pruritus, dry skin, alopecia, and exacerbation of autoimmune processes, particularly psoriasis, lichen planus, vitiligo, and tongue hyperpigmentation are the major skin lesions observed during combined treatment [3,4,5,6,7].

Secondary hyperpigmentation associated with peginterferon alpha-2b has been reported in the literature. However, as far as we know, there are

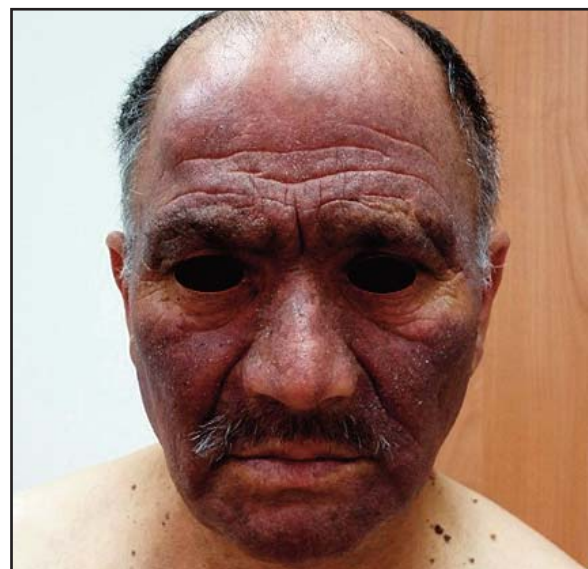


Figure 1. Hyperpigmented patches on forehead, on nose, on malar region, on chin, on the v of the neck

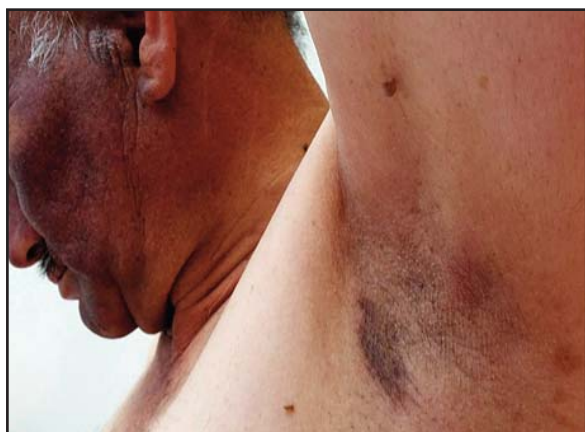

Figure 2. Hyperpigmented patches on the axillary area

no case studies in the literature about development of secondary pigmentations in the sun-exposed areas and axillar area during combined peginterferon alpha-2a and ribavirin treatment. We put forward a case report about the development of secondary pigmentation in the sun-exposed areas and during combined peginterferon alpha-2a and ribavirin treatment of a HCV infection.

Case Report

A sixty-one year old male that was previously diagnosed with HCV infection came to our dermatology clinic with complaints of darkening on his face and his axilla. The patient was on pegylated interferon-alpha 2a (180 µg weekly) and ribavirin (1,000 mg daily). At the dermatological examination on the fifth week of the therapy, there were symmetric, and dark brown pigmented patches on forehead, on malar region, on chin, on the v of the neck, and on the outer axilla (**Figures 1 and 2**). The patient's skin type was type III. The dermoscopy showed signs of pigmentary incontinence. The patient did not have a history of sun exposure and the hyperpigmentation was developed during winter. On the patient, there was no endocrinal pathology that could cause the hyperpigmentation. Furthermore, he had no history of cosmetics or drug use that could cause the hyperpigmentation. Punch biopsy was taken from the hyperpigmented areas and its histopathology was determined pigment accumulation and solar elastosis at the dermis (**Figure 3**).

Discussion

During the HCV infection combined PEGINF and ribavirin treatment, secondary hyperpigmentation can be seen on the skin, nails and

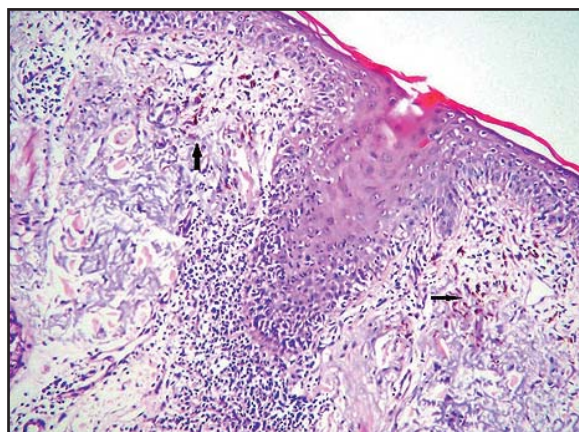


Figure 3. Pigment accumulation and solar elastosis at the dermis (Hematoxylin eosin X 200)

mucosa [4]. However, it is a quite rare case and there are few studies about such cases.

In the study done by *Tsilika et al*, on seven of the 77 patients (9%), secondary hyperpigmentation was observed during combined pegylated interferon alpha-2b plus ribavirin-treatment [8]. Moreover, *Gurguta et al* reported in their study that five of the 171 patients under combined pegylated interferon alpha-2b plus ribavirin treatment have developed secondary hyperpigmentation [4]. Apart from these works mentioned, there are few case reports about a development of secondary hyperpigmentation during combined pegylated interferon alpha-2b plus ribavirin treatment and most of those studies are about secondary oral pigmentation development.

In our case, in the fifth week of combined pegylated interferon alpha-2b plus ribavirin treatment, development of secondary hyperpigmentation was observed on the areas that were exposed to sun. Furthermore, there was no history of secondary hyperpigmentation causes such as sun exposure, hemochromatosis, Addison's disease, hyperthyroidism, porphyria cutanea tarda, or the use of cosmetics or drugs.

Hyperpigmentation development mechanism during HCV infection treatment is not fully understood. However, it has been reported that among dark skinned patients, plasma alpha-melanocyte-stimulating hormone (alpha-MSH) is generally higher and that they are more susceptible to hyperpigmentation development. Although not for certain, it is predicted that hyperpigmentation is caused by interferons stimulation of the alpha-MSG

hormone receptors, which causes increase in the melanin production [9].

As a result, there is a need for more comprehensive studies concerning the occurrences of side effects during PEG-INF-2a plus and ribavirin combination therapies. However, we think that the development of secondary hyperpigmentation on the face, which was an important cosmetic problem, is a side effect of PEG-INF-2a plus and ribavirin combined therapy.

Conflict of Interest

The authors declare that they have no conflict of interest.

References

1. Berk DR, Mallory SB, Keeffe EB, Ahmed A. Dermatologic disorders associated with chronic hepatitis C: effect of interferon therapy. *Clin Gastroenterol Hepatol* 2007; 5: 142-151. PMID: 16919505
2. Doutre MS. Hepatitis C virus-related skin diseases. *Arch Dermatol* 1999; 135: 1401-1403. PMID: 10566842
3. Dalekos GN, Christodoulou D, Kitis KG, Zervou EK, Hatzis J, Tsianos EV. A prospective evaluation of dermatological sideeffects during alfa-interferon therapy for chronic viral hepatitis. *Eur J Gastroenterol Hepatol* 1998; 10: 933-939. PMID: 9872615
4. Gurguta C, Kauer C, Bergholz U, Formann E, Steindl-Munda P, Ferenci P. Tongue and skin hyperpigmentation during PEGinterferon- alpha/ribavirin therapy in dark skinned non-Caucasian patients with chronic hepatitis C. *Am J Gastroenterol*. 2006; 101: 197-198. PMID: 16405555
5. Sookoian S, Neglia V, Castano G, Frider B, Kien MC, Chohuela C. High prevalence of cutaneous reactions to interferon alfa plus ribavirin combination therapy in patients with chronic hepatitis C virus. *Arch Dermatol* 1999; 135: 1000-1001. PMID: 10456365
6. Arya V, Bansal M, Girard L, Arya S, Valluri A. Vitiligo at Injection Site of PEG-IFN-α 2a in Two Patients with Chronic Hepatitis C: Case Report and Literature Review. *Case Rep Dermatol* 2010; 2: 156-164. PMID: 21076689
7. Torres HA, Bull L, Arduino RC, Barnett BJ. Tongue hyperpigmentation in a Caucasian patient coinfectd with HIV and hepatitis C during peginterferon alfa-2b and ribavirin therapy. *Am J Gastroenterol* 2007; 102: 1334-1335. PMID: 17531028
8. Tsilika K, Tran A, Trucchi R, Pop S, Anty R, Cardot-Leccia N, Lacour JP, Ortonne JP, Passeron T. Secondary hyperpigmentation during interferon alfa treatment for chronic hepatitis C virus infection. *JAMA Dermatol* 2013; 149: 675-677. PMID: 23553009
9. Willems M, Munte K, Vrolijk JM, et al. Hyperpigmentation during interferon alpha therapy for chronic hepatitis C virus infection. *Br J Dermatol* 2003; 149: 390-394. PMID: 12932249