

Atypical Swelling On Extremities of A Newborn Due To Iatrogenic Calcinosis Cutis

Serdar Alan,¹ MD, Ömer Erdeve,² MD, Dilek Kahvecioglu,² MD, Duran Yıldız,² MD, Ufuk Çakır,² MD, Hasan Akduman,² MD, Begüm Atasay,² MD, Saadet Arsan²

Address: ¹Neonatal Intensive Care Unit, Hitit University Corum Training and Research Hospital, Corum, ²Division of Neonatology, Department of Pediatrics, Ankara University School of Medicine, Ankara, Turkey

E-mail: alanserdar@gmail.com

* Corresponding Author: Dr. Serdar Alan, Neonatal Intensive Care Unit, Hitit University Corum Training and Research Hospital, Corum, Turkey.

Published:

J Turk Acad Dermatol 2015; 9 (3): 1593c5

This article is available from: <http://www.jtad.org/2015/3/jtad1593c5.pdf>

Keywords: Calcinosis cutis, iatrogenic, newborn, swelling

Abstract

Observation: This case report describes atypical presentation of iatrogenic calcinosis cutis in neonate. Iatrogenic calcinosis cutis usually presents by swelling erythema, induration, and soft tissue necrosis. Thus calcinosis cutis is usually easy to diagnose for clinicians. However, when extravasation is minor, the etiological relation of extravasation and calcification may not be obvious. Because of these reason, radiological findings are very important and they are usually the key to the diagnosis. A careful differential diagnosis from hematoma, abscess, or cellulitis prevent the patients from misdiagnosed and overtreatment.

Introduction

Calcinosis cutis, which is also called subcutaneous calcium deposits, is characterized by abnormal deposits of calcium salts in the dermis and/or hypodermis [1]. This uncommon disorder has been reported only as case presentation in newborns and it is classically categorized into three types: metastatic, dystrophic, and idiopathic [2, 3, 4]. We here report an atypical iatrogenic calcinosis cutis case without local erythema and ulceration of intravenous calcium therapy in a term newborn.

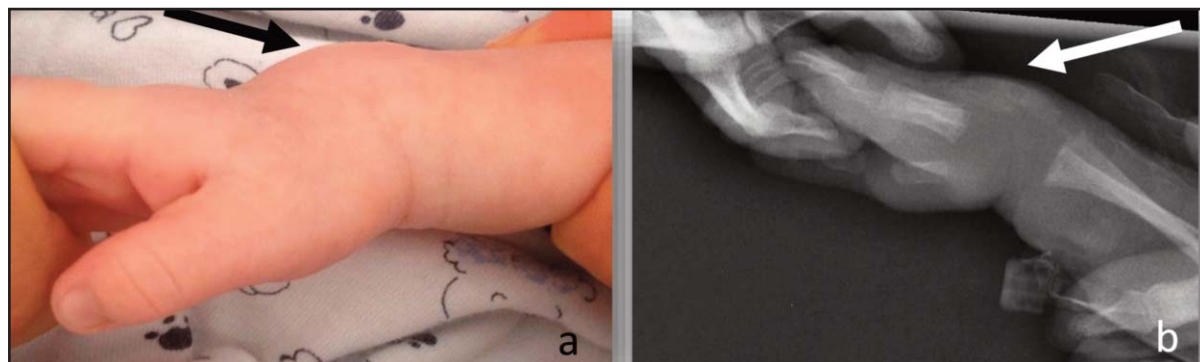
Case Report

A 3550-g male newborn was born vaginally to a 20-year-old mother at 396/7 gestational weeks after an uneventful pregnancy. He had neonatal hyperbilirubinemia due to ABO incompatibility and underwent phototherapy on the 2nd day of life. Routine clinical biochemical analysis on 3rd day of life revealed hypocalcemia (6.8 mg/dl, N:

8.5-10.1), hyperphosphatemia (7.2 mg/dl, N: 2.5-4.5), hypomagnesemia (1.26, 1.8-2.6 mg/dl) in addition to mildly high serum parathyroid hormone (PTH) (65.9 pg/ml, N:15-65) and low 25 OH-vitamin D levels (9.3 µg/L, N:25-80). The other laboratory analysis including serum alkaline phosphatase (ALP), thyroid function test, renal functions and urine analysis were normal. Maternal laboratory analysis were normal except for low 25 OH-vitamin D level.

The patient received 10% calcium gluconate (300 mg/kg/day) intravenously and 1200 U/day vitamin D (D-vit 3®, Deva, Istanbul-Turkey) orally for early neonatal hypocalcemia due to maternal 25 OH-vitamin D deficiency. Daily calcium gluconate was infused intravenously as divided into four doses in 4 ml of normal saline. Elementary oral calcium lactate (50 mg/kg/day) was started after 4 days of intravenous calcium and lasted upto two days prior to discharge. The patient was discharged with only vitamin D supplement as 1200 U/day on postnatal 11th day of life.

He was rehospitalized to the neonatal intensive care unit due to fever (38°C) and swelling on the



Figures 1a and b. Swelling without erythema, necrosis and ulceration, was observed on dorsum of the right wrist (a); Radiograph of the right forearm showed mild extraosseous calcification extending over the right uncle (b)

dorsum of right wrist, left forearm and medial side of right ankle 8 days after the discharge. Swellings were confined properly without erythema or ulceration and were non-fluctuant with the largest size of 2x3 cm (**Figure 1a**). Lesion sites on extremities were appropriate with application of intravenous calcium infusions on his previous hospitalization. The patient had sign of rapidly increasing swelling without erythema on the right wrist within one day.

Radiographs of the right forearm showed extra-osseous calcification extending over the right uncle (**Figure 1b**). Ultrasonography revealed hypertrophy of subcutaneous soft tissue without cystic or solid mass. His abdominal, renal and cranial ultrasonographies and echocardiography were normal. His laboratory evaluation was also in normal ranges and therefore hematoma, abscess and cellulitis were excluded in differential diagnosis. Iatrogenic calcinosis cutis was diagnosed both clinically and radiologically. Vitamin D treatment was reduced to 400 IU/day and he was discharged after 4 days of hospitalization. All swellings on extremities disappeared without any treatment within two month on outpatient follow-up.

Discussion

The clinicoradiological diagnosis of this case was iatrogenic calcinosis cutis due to intravenous calcium therapy. Although iatrogenic calcinosis cutis with extravasation of calcium therapy or secondary to trauma have been reported in the literature, cases without erythema or ulceration were very rare especially in newborns [2, 4, 5].

Calcinosis cutis is separated into five subtypes as dystrophic calcification, metastatic calcification, idiopathic calcification, iatrogenic calcification, and calciphylaxis according to recent data [6]. Dystrophic calcinosis cutis

occurs in damaged and traumatized tissues and the serum calcium and phosphorus levels are normal ranges. Calcium deposits appear in previously inflamed, degenerated, or neoplastic tissues, and cutaneous involvement is a common feature [1, 7, 8]. Metastatic calcification is characterized by an abnormal calcium and/or phosphate metabolism, leading to the precipitation of calcium in cutaneous and subcutaneous tissue. Idiopathic calcification occurs without any underlying tissue damage or metabolic disorder. Calciphylaxis presents with small vessel calcification mainly affecting blood vessels of the dermis or subcutaneous fat. Disturbances in calcium and phosphate metabolism and hyperparathyroidism can be observed [6].

Iatrogenic calcinosis cutis has various causes including intravenous calcium therapy which can occur with or without extravasation of calcium solution. Tissue damage and transient elevation of the local calcium concentration are the theories for iatrogenic calcinosis cutis. Some of these lesions are observed in low birth-weight babies subjected to multiple heel pricks in intensive care units. Local tissue injury increases cell membrane permeability, allowing cytosolic influx of calcium that exceeds the capacity of mitochondria to sequester calcium and phosphate. Thus, calcium phosphates are precipitated in the cytoplasm. In calcinosis that is caused by extravasated calcium, the primary pathologic alterations described are collagen degeneration and soft-tissue necrosis [1].

Swellings were observed 8 days after the end of intravenous calcium therapy in our patient. The lesions generally appear with an average of 13 days after the extravasation of the

calcium solution, with a range of 2 h to 24 days [1, 5]. Radiological changes are seen as early as 4–5 days and maximal radiological changes are present at about 2 weeks. The radiological findings are of great importance because they are usually the key to the diagnosis, which may be otherwise not clinically suspected [3]. Gradual resolution usually takes several months like our patient [1]. There is no specific mode of treatment except supportive management and (if necessary) a skin graft. Most infants completely recover without functional deficit [1, 3, 6].

When massive extravasation of calcium infusion is followed by swelling erythema, induration, and soft tissue necrosis, calcinosis cutis is usually easy to diagnose [3]. However, when extravasation is minor, the etiological relation of extravasation and calcification may not be obvious. In such cases, calcinosis cutis has been diagnosed as a hematoma, abscess, or cellulitis and treated as such; therefore, a careful differential diagnosis is necessary [8]. In our case, lesions presented as soft tissue swelling without erythema, necrosis or ulceration. In order to avoid over-diagnose and unnecessary treatment, calcinosis cutis should be considered especially in patients who experienced intravenous calcium treatment.

References

1. Puvabanditsin S, Garrow E, Titapiwatanakun R, Getachew R, Patel JB. Severe calcinosis cutis in an infant. *Pediatr Radiol* 2005; 35: 539-542. PMID: 15565339
2. Chen TK, Yang CY, Chen SJ. Calcinosis cutis complicated by compartment syndrome following extravasation of calcium gluconate in a neonate: a case report. *Pediatr Neonatol* 2010; 51: 238-241. PMID: 20713289
3. Sonohata M, Akiyama T, Fujita I, Asami A, Mawatari M, Hotokebuchi T. Neonate with calcinosis cutis following extravasation of calcium gluconate. *J Orthop Sci* 2008; 13: 269-272. PMID: 18528663
4. Sahn EE, Smith DJ. Annular dystrophic calcinosis cutis in an infant. *J Am Acad Dermatol* 1992; 26: 1015-1017. PMID: 1607402
5. Soon SL, Chen S, Warshaw E, Caughman SW. Calcinosis cutis as a complication of parenteral calcium gluconate therapy. *J Pediatr* 2001; 138: 778. PMID: 11343063
6. Reiter N, El-Shabrawi L, Leinweber B, Berghold A, Aberer E. Calcinosis cutis. Part I: diagnostic pathway. *J Am Acad Dermatol* 2011; 65: 1-12. PMID: 21679810
7. Rodriguez-Cano L, Garcia-Patos V, Creus M, Bastida P, Ortega JJ, Castells A. Childhood calcinosis cutis. *Pediatr Dermatol* 1996; 13: 114-117. PMID: 9122066
8. Arora A, Agarwal A, Kumar S, Gupta SK. Iatrogenic calcinosis cutis--a rare differential diagnosis of soft-tissue infection in a neonate: a case report. *J Orthop Surg* 2005; 13: 195-198. PMID: 16131687