

Milia Following Bullous Mastocytosis

Şule Güngör,^{1*} MD, Nedim Polat,² MD, Gonca Gökdemir,¹ MD, Dilek Canat,¹ MD

Address: ¹Department of Dermatology, Okmeydanı Training and Research Hospital, ²Department of Pathology, Şişli Etfal Training and Research Hospital, Istanbul, Turkey.

E-mail: drsulegungor@yahoo.com

* Corresponding Author: Şule Güngör, MD, Okmeydanı Training and Research Hospital, Dermatology Department, Istanbul, Turkey.

Published:

J Turk Acad Dermatol 2014; 8 (3): 1483c2

This article is available from: <http://www.jtad.org/2014/3/jtad1483c2.pdf>

Key Words: Bullous mastocytosis, milia, bullae

Abstract

Observation: Cutaneous mastocytosis (CM) is characterized by a pathologic increase in the number of mast cells in cutaneous tissues. Although bullae can occur in all forms of CM, bullous eruption is most commonly associated with diffuse CM (DCM) and is known as bullous mastocytosis (BM). Herein we report an 18-month-old male diagnosed as BM complicated by milia. To the best of our knowledge the present case report is the first to describe BM complicated by milia.

Introduction

Mastocytosis is characterized by a pathologic increase in the number of mast cells, frequently in cutaneous tissues and sometimes in such extracutaneous organs as the liver, spleen, lymph nodes, and bone marrow [1, 2]. Although bullae can occur in all forms of cutaneous mastocytosis (CM), bullous eruption is most commonly associated with diffuse CM (DCM) and is known as bullous mastocytosis (BM) [3, 4]. Herein we report an 18-month-old male diagnosed as BM complicated by milia.

Case Report

A 18-month-old male presented with a 6-month history of generalized blisters. His parents reported that the eruptions usually healed spontaneously, but that on a few occasions emergency department medical treatment was necessary. They also reported that after the bullous eruptions

healed crusts developed, followed by dissipation of the crusts and small point-like white formations. The patient's parents were not consanguine and they reported a negative family history of genodermatoses. Physical examination showed multiple, tense vesicle-bullae, erosions on urticarial plaques surrounded by hypo-hyperpigmented macules, and multiple, discrete, firm, white, 1-2-mm papules on the trunk.

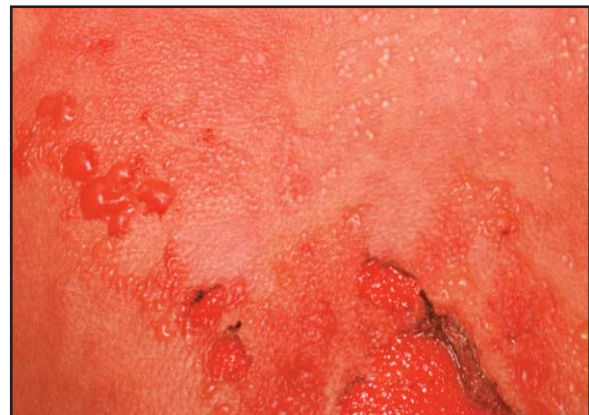

Figure 1. Multiple, tense vesicle-bullae, erosions on urticarial plaques, and multiple, discrete, firm, white, 1-2-mm papules on the trunk.

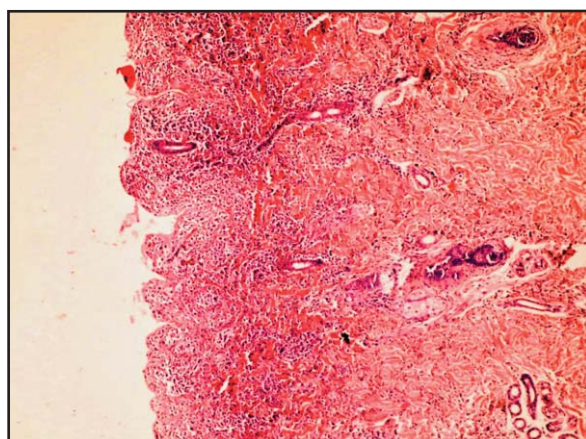


Figure 2. Suprabasal separation (epidermal layer could not be seen), and dense infiltration of mast cells and eosinophils in the papillary and upper reticular dermis. (Hematoxylin-eosin stain; original magnification X 10)

les on the scalp and trunk (**Figure 1**). Additionally, labial and palpebral edema was observed. Darier's sign was noted after rubbing the skin.

In consideration of the diagnoses of epidermolysis bullosa acquisita, BM, and chronic bullous disease of childhood, 2 punch biopsies were performed?1 from the lesional skin and 1 from perilesional normal skin. Histopathological examination of the specimens showed suprabasal separation (epidermal layer could not be seen), and dense infiltration of mast cells and eosinophils in the papillary and upper reticular dermis (**Figure 2**). Giemsa staining showed that the infiltrating cells in the dermis were mast cells (**Figure 3**). Direct immunofluorescence did not show immune deposition. The diagnosis of BM was made on the basis of the clinical presentation and histopathological findings.

Complete blood count, peripheral blood smear, chemistry profile, abdominal ultrasonography, and skeletal X-ray were normal. To suppress the patient's acute systemic symptoms parenteral methylprednisolone (for 3 days), oral antihistaminics and topical antiseptic pomade were prescribed. The patient's parents received counseling about avoiding mast cell degranulators, such as specific foods, medications, allergens, and some physical conditions. As of the time this manuscript was written the patient was being followed-up closely to maintain suppression of systemic symptoms and to evaluate systemic involvement.

Discussion

Although bullae can occur in all forms of CM, they are most commonly associated with DCM [4, 5, 6]. When DCM presents as bullous lesi-

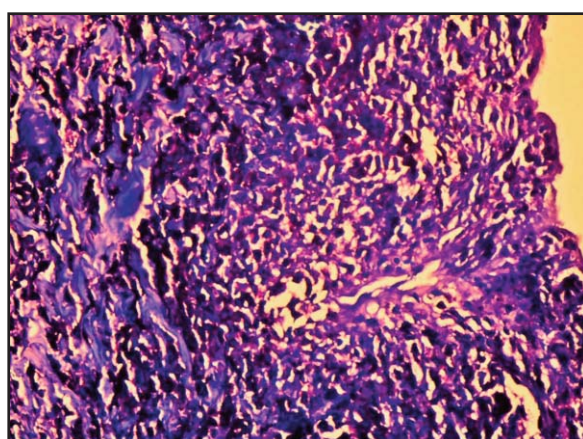


Figure 3. Mast cells infiltrating in the dermis. (Giemsa stain; original magnificationX40)

ons, it is referred to as BM [4]. Bullae can be tense, can contain serohemorrhagic fluid, and can rupture, resulting in erosions and crusts. The blisters are thought to result from serine proteases released by mast cells [6].

BM has a poor prognosis, due to its high rate of transformation to systemic mastocytosis [3, 7]. Even in the absence of systemic involvement; such systemic symptoms as hypotension, anaphylaxis, and severe diarrhea can be life threatening because of the high concentration of mast cell mediators [2, 6]. Fortunately, as with other forms of CM the symptoms in patients with BM decrease in severity over time and usually resolve spontaneously between the ages of 15 months and 5 years. But in the literature there are fatal cases probably severe complications due to mast-cell mediators [6, 8]. Due to the high rate of systemic involvement and severe anaphylactic reactions such patients should be monitored closely [6]. The presented patient did not have any systemic involvement or complications.

The diagnosis of BM is based on clinical features and histopathological findings. Diagnostic confirmation and differentiation from other bullous diseases requires histopathological examination and, sometimes, direct immunofluorescence (DIF) [2, 3]. Negative DIF results help rule out epidermolysis bullosa acquisita and chronic bullous disease of childhood.

Various bullous diseases, particularly epidermolysis bullosa and porphyria cutanea tarda, can heal with milia that are known as secondary milia [9]. Secondary milia are small epidermal cysts caused by proliferation of epithelium following injury to the dermoepi-

dermal junction [9, 10, 11]. Secondary milia following bullous pemphigoid, herpes zoster, contact dermatitis, bullous lupus erythematosus, bullous polymorphic light eruption, Sweet syndrome, lichen sclerosus, bullous erysipelas, lichen planus, and bullous amyloidosis have been reported [9, 10, 11, 12, 13, 14, 15]. To the best of our knowledge the present case report is the first to describe BM complicated by milia.

References

1. Baykal C, Yazganoğlu D. Mastositozlar. *Turkiye Klinikleri J Pediatr Sci* 2005; 1: 74-78.
2. Castells M, Metcalfe DD, Escibano L. Diagnosis and treatment of cutaneous mastocytosis in children. *Am J Clin Dermatol* 2011; 12: 259-270. PMID: 21668033
3. Lee EH, Kim MR, Kang TW, et al. Diffuse cutaneous mastocytosis with generalized bullae. *Ann Dermatol* 2010; 22: 77-80. PMID: 20548889
4. Silva I, Carvalho S, Pinto PL, et al. Mastocytosis: a rare case of anaphylaxis in paediatric age and literature review. *Allergol Immunopathol (Madr)* 2008; 36: 154-163. PMID: 18680704
5. İkizoğlu G, Köktürk A, Baz K, et al. A case of bullous mastocytosis. *Turkiye Klinikleri J Dermatol* 2008; 18: 208-211.
6. Ghiasi M, Ghanadan A, Jesri JB, et al. Diffuse cutaneous mastocytosis: Report of severe case with fatal outcome. *Dermatology Online Journal* 17: 7. PMID: 21426873
7. Murphy M, Walsh D, Drumm B, et al. Bullous mastocytosis: a fatal outcome. *Pediatr Dermatol* 1999; 16: 452-455. PMID: 10632943
8. Kiszewski AE, Duran MC, Orozco CL, et al. Cutaneous mastocytosis in children: a clinical analysis of 71 cases. *J Eur Acad Dermatol Venereol* 2004; 18: 285-290. PMID: 15096137
9. Berk DR, Bayliss SJ. Milia: A review and classification. *J Am Acad Dermatol* 2008; 59: 1050-1063. PMID: 18819726
10. Livideanu CB, Ammoury A, Viraben R, et al. Milia complicating bullous polymorphic light eruption. *Photodermatol, Photoimmunol, Photomed* 2009; 25: 51-52. PMID: 19152517
11. Thormann H, Andersen KE. Milia as sequelae to allergic contact dermatitis. *Contact Dermatitis* 2005; 53: 239-240. PMID: 16191028
12. Eckman JA, Mutasim DF. Bullous systemic lupus erythematosus with milia and calcinosis. *Cutis* 2002; 70: 31-34. PMID: 12184671
13. Lucke T, Fallowfield M, Burden D. Lichen planus associated with milia. *Clin Exp Dermatol* 1999; 24: 266-269. PMID: 10457126
14. Lee WS, Kim SJ, Ahn SK, et al. Milia arising in herpes zoster scars. *J Dermatol* 1996; 23: 556-558. PMID: 8854589
15. Lapidoth M, Hodak E, Segal R, et al. Secondary milia following bullous erysipelas. *Cutis* 1994; 56: 403-404. PMID: 7867383