

## Annular Elastolytic Giant Cell Granuloma in a 53-year-old man Associated with Diabetes Mellitus

Göknur Kalkan,<sup>1</sup> MD, Mehmet Akif Kuzey,<sup>2</sup> MD, Ümran Yıldırım,<sup>3</sup> MD, Akgül Arıcı,<sup>4</sup> MD

Address: <sup>1</sup>Department of Dermatology, Gaziosmanpasa University School of Medicine, Tokat, <sup>2</sup>Tokat Erbaa State Hospital, Tokat, Department of Pathology, <sup>3</sup>Fatih University, School of Medicine, Ankara, <sup>4</sup>Department of Pathology, Gaziosmanpasa University School of Medicine, Tokat

E-mail: goknurkalkan@yahoo.com

\* Corresponding Author: Göknur Kalkan, MD, Department of Dermatology, Gaziosmanpasa University School of Medicine, Tokat, 60100 Turkey

Published:

J Turk Acad Dermatol 2013; 7 (3): 1373c5

This article is available from: <http://www.jtad.org/2013/3/jtad1373c5.pdf>

**Key Words:** annular elastolytic giant cell granuloma; diabetes mellitus

### Abstract

**Observation:** Annular elastolytic giant cell granuloma (AEGCG), a rare granulomatous dermatosis, clinically presents as annular plaques with slightly elevated margins, and atrophic centers and histologically characterized by phagocytosis of elastic fibers by multinucleated giant cells. The pathogenesis of AEGCG has not been identified enough yet. It has been postulated that AEGCG is associated with systemic disorders such as diabetes mellitus. AEGCG is primarily observed in sun-exposed areas of middle-aged women. However, some cases of AEGCG involving the regions not exposed to sun have been described. Here we report a case of a 53-year-old male patient with diabetes mellitus (DM) diagnosed as AEGCG clinically and histopathologically that has also lesions on uncovered areas as well as sun exposed areas and review the literature about this distinct entity.

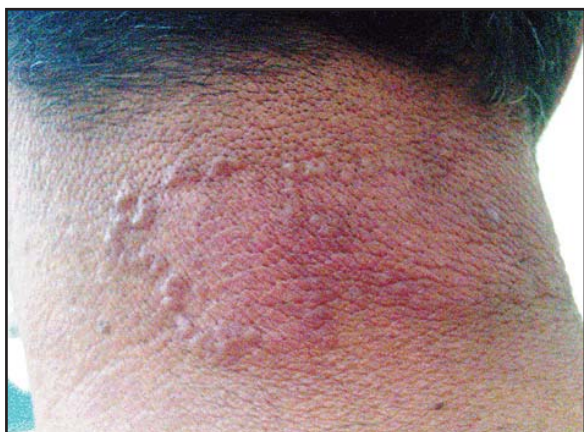### Introduction

Annular elastolytic giant cell granuloma (AEGCG) is a rare granulomatous skin disease, which is characterized histologically by an absence of elastic fibres, due to elastophagocytosis by multinucleated giant cells in the dermis [1]. Lesions of AEGCG are mostly found in middle-aged white women, usually located on sun exposed areas and rarely on covered areas. The pathogenesis of AEGCG can not be illuminated yet but there have been reports of AEGCG associated with systemic disorders [2, 3]. Here we report a case of a 53-year-old male patient with diabetes mellitus (DM) diagnosed as AEGCG clinically and histopathologically that has also lesions on uncovered areas as well as sun exposed areas

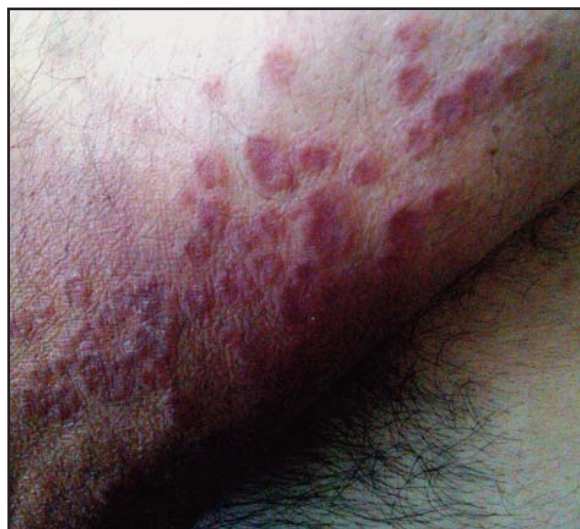and review the literature about this distinct entity.

### Case Report

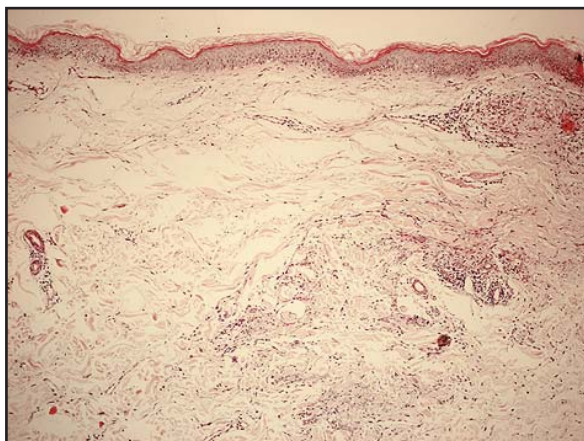
A 54-year-old man presented with a 3-year history of asymptomatic and diffuse skin lesions consisting of annular red plaques located on the nape, upper limbs, hands and the trunk. The patient declared that these lesions first appeared on his hands and gradually spreaded to the other parts of the body. He pointed out that he could not benefit from the topical treatments enough which were recommended in several medical centers. He was a hod carrier and he remarked that he did not work without his clothes in terms of sun exposure. The man's personal history included type 2 diabetes mellitus for four years. According to the patient, the control of diabetes did not change the



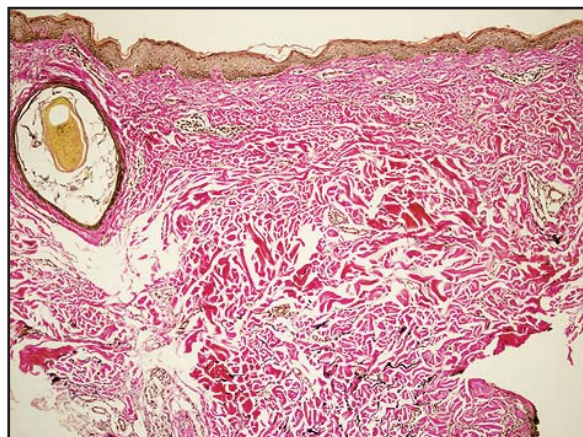
**Figure 1.** Annular erythematous lesions on the nape of the neck



**Figure 2.** Annular erythematous papules and atrophic plaques with elevated border and on the arm



**Figure 3.** Dermal infiltrate of perivascular lymphocyte and plasmacyte infiltration and multinucleated giant cells and macrophages, some of which contained fragments of damaged elastic tissue and absence of elastic fibres in the dermal centre of the lesion (H&E, x 25)



**Figure 4.** Thinning, fragmentation and absence of elastic fibres (elasti van Gieson, X 25)

progression of the skin lesions. His family history was unremarkable by means of any systemic or dermatological diseases. The patient was completely asymptomatic. Dermatological examination revealed asymmetric erythematous papules and atrophic plaques with slightly elevated border and annular configuration on the nape of the neck, trunk, arms, and forearms (**Figures 1 and 2**).

Histological examination revealed dermal infiltrate of multinucleated giant cells and macrophages, some of which contained fragments of actinically damaged elastic tissue (elastophagocytosis), and loss of elastic fibers in the center of the lesion. There was absence of necrobiosis and mucin (**Figure 3**). Since the patient stated that topical treatments previously used were unsatisfactory, a treatment model of hydroxychloroquine 400 mg/d has been started and the patient is still in our follow-up.

## Discussion

AEGCG is a rare granulomatous skin disease described by *Hanke et al.* in 1979 as a separate disease entity [4]. The pathogenesis of AEGCG is still unknown. It is suggested that ultraviolet radiation, heat or other unknown factors might change the antigenicity of elastic fibres which may activate a cellular immune reaction directed to them. This theory is supported by immunohistochemical findings of an increased CD4/CD8 T-cell ratio [5]. It has been also proposed that diabetes mellitus could be implicated in the etiology by producing structural damage of the elastic tissue [6]. A recent Japanese report demonstrated the possible role of DM in the structural damage of the elastic fibers [7]. Only a few cases of AEGCG associated with DM have been repor-



ted in the English literature [3, 8]. The patient presented here also had a diagnosis of DM for four years. The lesions of AEGCG have been developed 1 year later. Further studies are needed to clarify the relationship between AEGCG and DM.

AEGCG is usually described in sun-exposed areas, such as face and neck and is rarely described on covered areas on the trunk, on the back and on the extremities. Lesions are either solitary or grouped in annular patches with elevated borders and central atrophy as seen in our patient [2, 9]. In the presented case here there were also lesions on the covered areas such as upper limbs and trunk in addition to sun-exposed areas. Therefore our case was distinct from the classical reported cases. Similar to our case Campos-Muñoz et al. presented a case of AEGCG in a male patient with atypical clinical manifestation on the non-sun exposed skin [10]. Oliveira et al. reported a case of generalized erythematous annular lesions in the upper limbs and trunk, showing an unusual location of the lesions [11]. Babuna et al. also reported recently a case of AEGCG in 55-year-old fair-skinned Turkish woman localized both on the sun-exposed and covered areas [12]. The unusual localization of the lesions on covered areas with no history of sun exposure proposes the idea that photosensitivity may not be the only factor in the etiopathogenesis of AEGCG.

Diagnosis is based on histopathological findings of a granulomatous reaction with elastolysis and phagocytosis of elastic fibers by multinucleated giant cells and the absence of elastic fibers in the center of the granuloma. Elastophagocytosis is a non-specific phenomenon that can also be found in cases of generalized granuloma annulare. However, in AEGG there is a distinct zone of elastophagocytosis, and the quantity and distribution of giant cells differ from those observed in GA. In addition, in AEGG there is no necrobiosis of collagen or mucin deposition and elastosis is absent in some cases [1, 4]. The histopathological findings of our case were consistent with the diagnostic features of AEGCG. The other diseases in differential diagnosis include sarcoidosis, annular lichen planus, lichenoid photosensitivity reactions, subacute cutaneous lupus erythematosus, and inflammatory mid dermal elastolysis [1, 12]. The relationship between GA and AEGG is the

subject of controversy. Some authors believe that AEGG is a type of GA preferentially located on sun exposed skin, while others believe it to be an entity in its own right. A hybrid pattern has been described in 5 cases indicating an aetiopathogenic overlap with the possible influence of systemic diseases such as DM [12, 13, 14].

The disease follows a chronic course, but there have been reports of spontaneous remission. The existence of various treatments for AEGCG unfortunately does not guarantee satisfactory results [12, 14]. Our case illustrates the nonresponsiveness to corticosteroids and other topical agents and we have started treatment with hydroxychloroquine in a daily dose of 400 mg because of the good response in previously reported cases.

## References

- Özkaya-Bayazit E, Büyükbabani N, Baykal, Öztürk A, Okçu M, Soyer HP. Annular elastolytic giant cell granuloma: sparing of a burn scar and successful treatment with chloroquine. Br J Dermatol 1999; 140: 525-530. PMID: 10233280
- Boussault P, Tucker ML, Weschler J et al. Primary cutaneous CD4+ small/medium-sized pleomorphic T-cell lymphoma associated with an annular elastolytic giant cell granuloma. Br J Dermatol 2009; 160: 1126-1128. PMID: 19292715
- Doulaveri G, Tsagrioni E, Giannadaki M et al. Annular elastolytic giant cell granuloma in a 70-year-old woman. Int J Dermatol 2003; 42: 290-291. PMID: 12694495
- Hanke CW, Bailin PL, Roenigk HH Jr. Annular elastolytic giant cell granuloma. A clinicopathologic study of five cases and a review of similar entities. J Am Acad Dermatol 1979; 1: 413-421. PMID: 512085
- Tsutsui K, Hirone T, Kubo K, Matsui Y. Annular elastolytic giant cell granuloma: response to cyclosporin A. J Dermatol 1994; 21: 426-429. PMID: 8064006
- Hideyuki K, Kitajima Y, Yaoita H. Annular elastolytic giant cell granuloma an unusual case with papular lesions. J Dermatol 1991; 18: 667-670. PMID: 1800533
- Aso Y, Izaki S, and Teraki Y. Annular elastolytic giant cell granuloma associated with diabetes mellitus: a case report and review of the Japanese literature. Clin Exp Dermatol 2011; 36: 917-919. PMID: 21623881
- Başak PY, Icke I, Akkaya VB, Başak K. Lack of response to isotretinoin in annular elastolytic giant cell granuloma. J Dermatol 2004; 31: 678-681. PMID: 15492443
- Pock L, Blaková J, Caloudová H, Varjassyová R, Konkolová J, Hercogová. Annular elastolytic giant cell granuloma causes an irreversible disappearance of

- the elastic fibres. *J Eur Acad Dermatol Venereol* 2004; 18: 365-368. PMID: 15096158
10. Campos-Muñoz L, Díaz-Díaz RM, Quesada-Cortés A, Hernández-Cano N, Martín-Díaz MA, Regojo-Zapata RM, Casado Jiménez M. Annular elastolytic giant cell granuloma: a case report located in non-sun exposed areas. *Acta Dermosifiliogr* 2006; 97: 533-535. PMID: 17067534
  11. de Oliveira FL, de Barros Silveira LK, Machado Ade M, Nery JA. Hybrid clinical and histopathological pattern in annular lesions: an overlap between annular elastolytic giant cell granuloma annulare? *Case Rep Dermatol Med* 2012; 2012: 102915. PMID: 23259076
  12. Babuna G, Büyükbabani N, Yazganoglu KD, Baykal C. Effective treatment with hydroxychloroquine in a case of annular elastolytic giant cell granuloma. *Indian J Dermatol Venereol Leprol* 2011; 77: 110-111. PMID: 21220900
  13. Ackerman AB, Chongchitnant N, Sanchez J et al. Histologic diagnosis of inflammatory skin diseases. An algorithmic method based on pattern analysis. 2th ed. Baltimore: Williams & Wilkins; 1997. p. 50-53.
  14. Limas C. The spectrum of primary cutaneous elastolytic granulomas and their distinction from granuloma annulare: a clinicopathological analysis. *Histopathology* 2004; 44: 277-282. PMID: 14987232