

Phenytoin Hypersensitivity Syndrome Associated with Glutathione S-Transferase, N-Acetyltransferase, Cytochrome P450 Polymorphisms

Ümit Türsen, MD, Lulufer Tamer,* MD, Kıymet Baz, MD, Ayça Cordan Yazıcı, MD, Hatice Yıldırım,* MD, Ayşe Polat,† MD, Güliz İkizoğlu, MD, Belma Türsen,†† MD

Address: Departments of Dermatology, *Biochemistry and †Pathology, University of Mersin, School of Medicine, †† Departments of Dermatology, Mersin State Hospital

E-mail: utursen@mersin.edu.tr

* Corresponding Author: Dr. Ümit Türsen, Mersin University, Faculty of Medicine, Zeytinlibahçe, 33079, Mersin, Turkey

Published:

J Turk Acad Dermatol 2012; 6 (3): 1263c2

This article is available from: <http://www.jtad.org/2012/3/jtad1263c2.pdf>

Key Words: Phenytoin-induced hypersensitivity syndrome, glutathione S-transferase, N-acetyltransferase, cytochrome P450 polymorphisms

Abstract

Observation: The anticonvulsant hypersensitivity syndrome is rare complication that occurs with the use of antiepileptic medications. All of the aromatic anticonvulsant drugs are metabolised by the cytochrome P-450 enzyme to a common arene oxide metabolite that is normally detoxified by epoxide hydrolase. A genetically determined inability to detoxify the toxic metabolites due to a defect in the enzyme epoxide hydrolase has been observed in patients with this hypersensitivity syndrome. We present a patient with severe phenytoin-induced hypersensitivity syndrome associated with glutathione S-transferase, N-acetyltransferase, and cytochrome P450 polymorphisms.

Introduction

Anticonvulsant hypersensitivity syndrome (AHS) is an adverse drug reaction associated with the aromatic anticonvulsant drugs phenytoin, carbamazepine phenobarbital, and primidone. The syndrome is defined by the triad of fever, rash, and symptomatic or asymptomatic internal organ involvement, including primarily hepatitis, nephritis, and lymphadenopathy [1]. The pathogenesis of AHS is not yet fully understood, but there is considerable evidence that the immune system plays a major role. Most of the facts suggest a hypersensitivity syndrome, although idiosyncratic and toxic mechanism with enzymatic induction of cytochrome P450 and the production of intermediary metabolites have also been involved. These metabolites are potentially cytotoxic, and they can alter

the lymphocyte function, increasing the hepatocellular necrosis and lymphadenopathies. All of the aromatic anticonvulsant drugs are metabolised by the cytochrome P-450. A genetically determined inability to detoxify the toxic metabolites due to a defect in the enzyme epoxide hydrolase has been observed in patients with AHS [2, 3, 4]. Acetylation, polymorphism is an important step the biotransformation of many in drugs and other arylamine xenobiotics. One of the well described and genetically determined polymorphic drug metabolism is the N-acetyltransferase 2 acetylation (NAT) polymorphism [5].

Some drugs use glutathione S-transferases (GST) as substrate. Recently, we observed that GST-M1 and GST-T1 gene polymorphisms seem to be associated with the deve-

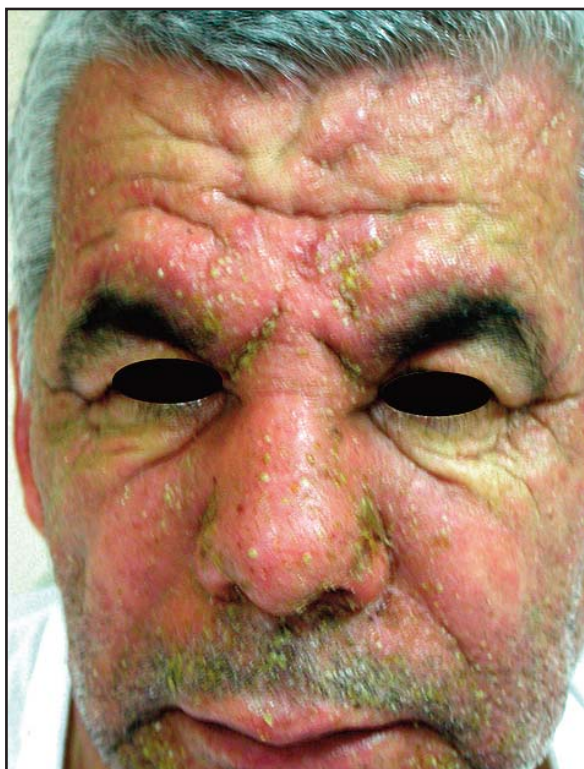


Figure 1. Maculopapular erythema and pustules with marked facial edema on the face

lopment of drug eruption [6]. Cytochrome P450 (CYP) are known to be involved in the metabolism of commonly used medication [7]. We present a patient with AHS to phenytoin who had GST-T1, GST-M1, NAT-5A, and CYP-450 polymorphisms.

Case Report

A 54-year-old man suffered a intracranial surgery and was started on phenytoin 200 mg daily. Twenty-nine days later, he developed a systemic illness with malaise and high fever. Two days after that, he presented with an extensive rash, and phenytoin was discontinued on day 35. There was a fine confluent erythematous maculopapular rash, which spread over the whole body. Examination revealed pyrexia (39° C), and erythroderma with oedema and pustules on the face (**Figure 1**). He had lymphadenopathy at the axillary and cervical regions without tenderness.

A blood count revealed a leukocytosis of $21 \times 10^3/\mu\text{L}$ (normal range: $4.5\text{--}11 \times 10^3/\mu\text{L}$), neutrophilia of $13 \times 10^3/\mu\text{L}$ (normal range: $1.5\text{--}6.7 \times 10^3/\mu\text{L}$), and eosinophilia of $1.4 \times 10^3/\mu\text{L}$ (normal range: $0.2\text{--}0.95 \times 10^3/\mu\text{L}$). Sedimentation rate was 19 mm/hr.

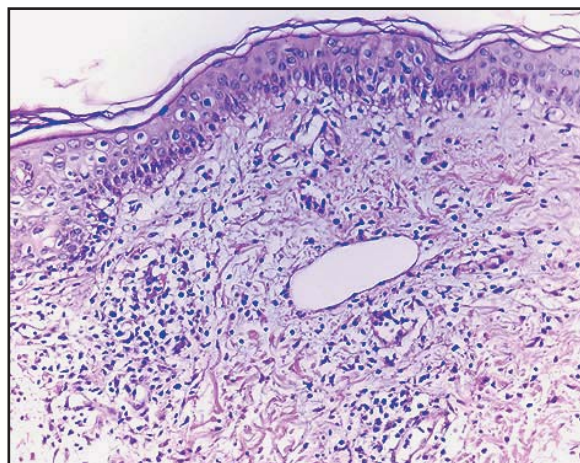


Figure 2. Perivascular and interstitial eosinophils and lymphocytes (Hematoxylin-Eosin, original magnification X 400)

The blood film showed eosinophilia. There were no atypical and reactive lymphocytes. He had hepatitis with a raised aspartate transaminase of 40 IU/L (normal range <38 IU/L), alanine transaminase of 102 IU/L (normal range <41 IU/L), and gamma-glutamyl transferase of 319 IU/L (normal range <49 IU/L). Renal function was impaired [urea level 135 mg/dl (normal range: 13-45 mg/dl); creatinine concentration 2.12 mg/dl (normal range <1.2 mg/dl); no proteinuria]. The rest of routine blood chemistry levels, urinalysis, and serum levels of triiodo-thyronine, thyroxine, thyroid stimulating hormone were normal. An infection screen, including Epstein-Barr serology (monospot test), cytomegalovirus IgM hepatitis B surface antigen, anti-hepatitis B surface antigen, anti-hepatitis B core IgM, anti-hepatitis C virus, HIV-1, 2 antibodies were negative, while anti-hepatitis B surface IgG was positive (enzyme immunoassay method). Antinuclear, anti-DNA, cANCA, anti-ENA, anti-RNP, anti-Sm, anti-SSA, anti-SSB, anti-Jo1, anti-Scl-70 antibodies were negative, and immunoglobulin G, A, M, and E, total C3 and C4 complement levels were normal. No remarkable findings were noted on chest X-ray and abdominal ultrasonography. Cultures from pustule swab for bacteria revealed no pathogenic growths. A skin biopsy specimen showed features superficial perivascular dermatitis in the form of individual necrotic epidermal keratinocytes, orthokeratosis, irregular hyperplasia, vacuolar changes and eosinophils in the dermal infiltrate (**Figure 2**). The diagnosis was AHS. After discontinuation of phenytoin, he was treated with oral corticosteroids (90 mg deflasocort daily) and systemic antihistamines (acrivastine 8 mg daily). The dose of corti-

steroids was gradually tapered within two weeks, and discontinued after 1 month. After treatment, the rash, fevers, and lymphadenopathy had resolved, and liver, renal function tests, complete blood count had progressively improved.

For genetic analysis, blood was collected in EDTA-containing tubes and DNA was extracted from the lymphocytes by high pure template preparation kit (Roche diagnostics, GmbH, Mannheim, Germany). The genotyping of polymorphisms of GSTT1, GSTM1 and GSTP1, were done using real time PCR with Light Cycler instrument using hybridization probes in combination with the Light Cycler DNA Master Hybridization Probes Kit (Roche diagnostics, GmbH, Mannheim, Germany). Both the PCR primers and hybridization probes were synthesized by TIB MOLBIOL (Berlin, Germany) for GST polymorphisms. NAT25A, NAT26A, NAT27A/B, NAT214A, CYP2C9*2 and CYP2C9*3 were done real time PCR with Light Cycler instrument using Light Cycler kits (Roche Diagnostics, GmbH, Mannheim, Germany).

In our patient, we investigated whether the genetic polymorphism of the NAT2 (NAT25A, NAT26A, NAT27A/B and NAT214A), GST polymorphisms (GSTT1, GSTM1 and GSTP1) and CYP2C9*2 and CYP2C9*3 play a role in susceptibility to AHS. We found that while NAT25A was mutant, NAT26A, NAT27A/B and NAT214A were wild genotype. While GSTT1 and M1 were positive, GSTP1 was heterozygote. CYP2C9*2 and CYP2C9*3 were wild type.

Discussion

AHS refers to a specific, severe, idiosyncratic drug reaction, which was first described with the use of phenytoin. It usually develops acutely, 2-8 weeks after initiation of therapy with aromatic anticonvulsant drugs. The syndrome is characterised by a severe morbilliform eruption, fever, lymphadenopathy, hepatitis, and hematologic abnormalities such as eosinophilia and atypical lymphocytes in the circulation. Although initially AHS was reported due to phenytoin, it can also be caused by carbamazepine and phenobarbital. There is frequent cross sensitivity between these drugs, which has been observed to be as high as 70-80% [1, 2]. All of aromatic anticonvulsant drugs are metabolized by the cytochrome P-450 enzyme to a common arene oxide metabolite that is normally detoxified by epoxide hydrolase. A genetically determined inability to detoxify the

toxic metabolites due to a defect in the enzyme epoxide hydrolase has been observed in patients with AHS. Defective detoxification may lead to cell death or contribute to formation of an antigen that triggers an immune response. [3, 4] Recently, GST, NAT, and CYP polymorphisms have been observed in some drug reactions. [5, 7]

The glutathione S-transferases (GST) are a multi-gene family of enzymes involved in the detoxification and, in a few instances, activation of a wide variety of chemical [6]. Some drugs such as acetaminophen, cyclophosphamide, chlorambucil, fosfomycin, adriamycin, cis-platin, bis-chloro-methyl nitrosourea, thiotepa, ethacrynic acid, nitroglycerine, menadione, mitozantrone use glutathione S-transferases as substrate [6, 8]. Five subclasses of the GST superfamily exist (Alpha, Pi, Mu, Theta, Zeta). Among these classes of GST; GSTM1, GSTM3, GSTT1, GSTP1, and GSTZ1 have been shown to be polymorphically distributed. A large quantity of GSTM1, GSTT1 and GSTP1 are expressed in the liver [8]. The subclass GSTP1 is widely expressed in normal human epithelial tissues. Three common polymorphisms in the GSTP1, GSTT1, and GSTM1 genes either decrease or abolish GST enzyme activity. A single nucleotide substitution (A-G) at position 313 of the GSTP1 gene, which results in replacing isoleucine with valine, substantially diminishes GSTP1 enzyme activity. By contrast, inherited homozygous deletions of the GSTT1 or GSTM1 gene leads to an absence of enzymatic activity. Recently, we observed that GST-M1 and GST-T1 gene polymorphisms seem to be associated with the development of drug eruption [6, 8]. Our patient had GST-M1 and GST-T1 gene polymorphisms.

Human arylamine N- acetyltransferases (NAT) are known to exist as two isoenzymes, NAT1 and NAT2, with different though overlapping substrate specificity. NAT are the enzymes present in the cells of most mammalian species. Two different genes code these enzymes: NAT1 and NAT2. Gene NAT1 is expressed in the cells of the majority of tissues and organs, whereas gene NAT2 only in the liver and intestine [6, 9]. Acetylation polymorphism is an important step the biotransformation of many in drugs and other arylamine xenobiotics. One of the well described and genetically determined polymorphic drug metabolism is the NAT2

acetylation polymorphism [5]. Acetylation polymorphism and resultant division into the fast and free acetylators is caused by the occurrence of gene wild allele NAT2 and its mutant forms. A given person shows the fast acetylation phenotype if at least one allele NAT2 is wild. The presence of mutation in both alleles NAT2 is manifested by the free acetylation phenotype (slow acetylator) [5, 9]. NAT-5A polymorphism was observed in our patient.

Many members of the cytochrome P450 (CYP) family are responsible for the metabolism of endogenous substrates, dietary compounds and environmental toxins. Additionally, CYP are known to be involved in the metabolism of commonly used medication. Each member of the CYP family has its preferred set of substrate: next to tolbutamide, phenytoin, and losartan, CYP2C9 has been shown to metabolise warfarin. Two known allelic variants CYP2C9*2 (C430T) and CYP2C9*3 (A1075C) differ from the wild type CYP2C9*1 by a single nucleotide substitution. Literature indicates that both allelic variants are associated with an impaired enzyme activity towards the respective substrate [7, 10]. Our patient had wild genotypes. This finding reflects a normal enzyme activity of CYP in our patient.

In early studies, genetically epoxide hydrolase defect has been observed in patients with AHS. In our patient with AHS, we indicated GST, and NAT polymorphisms, which this reflects defective enzyme activities of GST and NAT. Our findings suggest that GST and NAT polymorphisms may contribute the etiopathogenesis of AHS. Further studies in larger patient series are needed to determine the prevalence and distribution of these polymorphisms in AHS and whether they constitute a major risk factor in the development of AHS.

References

1. Scheuerman O, Moses YN, Rachmel A, Ashkenazi S. Successful treatment of antiepileptic drug hypersensitivity syndrome with intravenous immune globulin. *Pediatrics* 2001; 107:1-2. PMID:1134478
2. Kaur S, Sarkar R, Thami GP, Kanwar AJ. Anticonvulsant hypersensitivity syndrome. *Pediatr Dermatol* 2002; 19: 142-145.
3. Shear NH, Speilberg SP. Anticonvulsant hypersensitivity syndrome: in vitro assessment of risk. *J Clin Invest* 1988; 82: 1826-1832. PMID:3198757
4. Speilberg SP, Gordon GB, Blake DA, Mellitus DE, Bross DS. Anticonvulsant toxicity in vitro. Possible role of arene oxides. *J Pharmacol Exp Ther* 1981; 217: 386-389. PMID:7229980
5. Sim E, Pinter K, Mushtag A, Upton A, Sandy J, Bhakta S, Noble M. Arylamine N-acetyltransferases: a pharmacogenomic approach to drug metabolism and endogenous function. *Biochem Soc Trans* 2003; 31: 615-619. PMID:12773167
6. Ates NA, Tursen U, Tamer L, Kanik A, Ikizoglu G. Glutathione S-transferase polymorphisms in patients with drug eruption. *Arch Dermatol Res* 2004; 295: 429-433. PMID:14740231
7. Tassies D, Freire C, Pijoan J, Maragall S, Monteagudo J, Ordinas A, Reverter JC. Pharmacogenetics of acenocoumarol: cytochrome P450 CYP2C9 polymorphisms influence dose requirements and stability of anticoagulation. *Heamatologia* 2002; 87: 1185-1191. PMID:12414349
8. Grevelink SV, Mulliken JB, Vascular Eaton DL, Bammler TK. Concise review of the glutathione S-transferases and their significance to toxicology. *Toxicol Sci* 1999; 49: 156-164. PMID:10416260
9. Pompeo F, Brooke E, Kawamura A, Mushtaq A, Sim E. The pharmacogenetics of NAT: structural aspects. *Pharmacogenomics* 2002; 3: 19-30. PMID:11966400
10. Aithal GP, Day CP, Kesteven P, Daly AK. Association of polymorphisms in the cytochrome P450 CYP2C9 with warfarin dose requirement and risk of bleeding complications. *Lancet* 1999; 353: 717-719. PMID:10073515